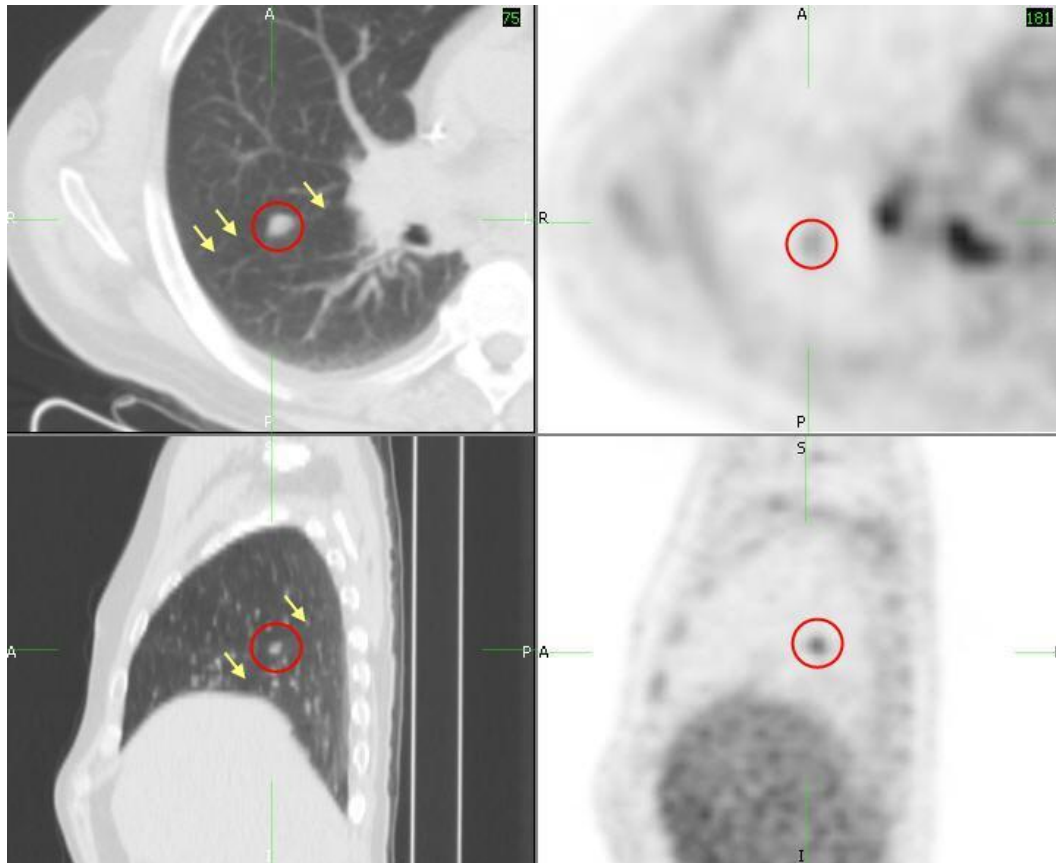


Case Study by James Buchino, MD

Diagnosis: Hodgkin Lymphoma with intrapulmonary lymph node involvement



Discussion:

The key to evaluating abnormalities identified on PET/CT is pattern recognition in combination with the patient's clinical history. As in this case, the pattern of lymphadenopathy would be very unusual for metastatic disease from primary lung cancer. Understanding the normal lymphatic drainage will often help differentiate different malignancies. Primary lung cancer drains from the lung parenchyma to the ipsilateral hilum with variable drainage into the mediastinum. The diffuse involvement of lymph nodes in the bilateral cervical regions (not shown), mediastinum, hila, and abdomen is more characteristic of lymphoma and consistent with the patient's history of Hodgkin disease. The abnormal focus of FDG accumulation in a small ovoid nodule along the major fissure most likely represents an intrapulmonary lymph node although superimposed lung cancer cannot be entirely excluded.

While primary pulmonary lymphoma is rare, 80% of patient's with Hodgkin disease have intrathoracic involvement at initial presentation. Most commonly there is anterior mediastinal and paratracheal lymphadenopathy with contiguous spread. Hodgkin disease and NHL are not reliably distinguished by the distribution and requires identification of the Reed-Sternberg cells associated with Hodgkin disease on histology. FDG PET/CT is recommended for staging, restaging, or in evaluation to therapy with a high degree of sensitivity and specificity for Hodgkin disease. Evaluation with PET/CT can be associated with false positives related to misinterpretation of nonspecific hypermetabolic regions such as brown fat as nodal or extranodal disease.

Hodgkin disease can be classified based on the Ann Arbor Staging system. Stage 1 involves a single lymph node region. Stage 2 disease involves multiple lymph node regions on the same side of the diaphragm whereas Stage 3 involves both sides of the diaphragm. Stages 2 and 3 can be further divided into 2E and 3E in the presence of localized extranodal disease. Stage 3S refers to extranodal involvement of the spleen. When there is diffuse extralymphatic involvement regardless of lymphadenopathy the patient is considered Stage 4. The extent and size of disease is important information utilized in both radiation therapy planning and prognosis. Bulky mediastinal lymphadenopathy is associated with increased risk of recurrence prompting more aggressive treatment with both chemotherapy and radiation.

Extralymphatic pulmonary involvement is more commonly associated with Hodgkin disease, but only identified in approximately 12% of patients at initial presentation. The appearance of extranodal parenchymal lung involvement is quite variable. The most common appearance is a mass or mass-like consolidation of the lung. However, parenchymal involvement may also manifest as a small solitary nodule, cavitary lesions or multiple small nodules resembling metastatic disease. There can also be peribronchial or perivascular invasion in a subsegmental or segmental distribution, which may be mistaken for pneumonia. Extralymphatic disease is also illustrated with direct invasion from mediastinal lymphadenopathy or a more diffuse reticular infiltrative pattern. While size criteria are often utilized to assist in the interpretation of mediastinal lymph nodes on CT with less than 1 cm in short axis considered normal, there is no size criteria for extrapleural lymph nodes. PET/CT can provide additional information than merely size by demonstrating the presence of hypermetabolic activity. This case demonstrates the advantage of PET/CT by showing abnormal FDG accumulation within the intrapulmonary lymph node suggesting lymphomatous involvement.

References:

Fishman, Elliot K., Janet E. Kuhlman, and Richard J. Jones. "CT of Lymphoma: Spectrum of Disease." *RadioGraphics*. 11. (1991): 647-669. Web. 29 Feb. 2012.

Sharma, Amita, Panos Fidias, L.Anne Hayman, Susanne L. Loomis, Katherine H. Taber, and Suzanne L. Aquino. "Patterns of Lymphadenopathy in Thoracic Malignancy." *RadioGraphics*. 24. (2004): 419-434. Web. 29 Feb. 2012.

Paes, Fabio M., Dimitrios G. Kalkanis, Panagiotis A. Sideras, and Aldo N. Serafini. "FDG PET/CT of Extranodal Involvement in Non-Hodgkin Lymphoma and Hodgkin Disease." *RadioGraphics*. 30. (2010): 269-291. Web. 29 Feb. 2012.