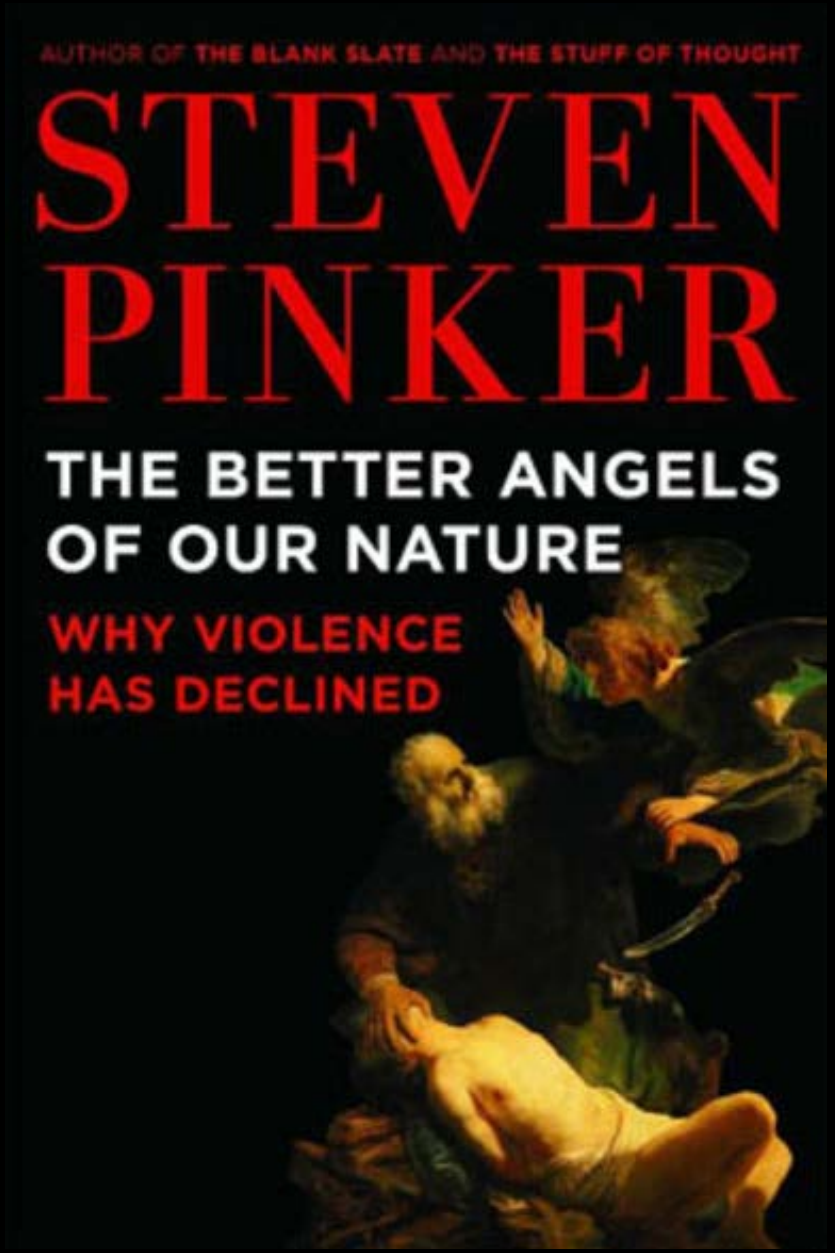
AUTHOR OF THE BLANK SLATE AND THE STUFF OF THOUGHT
STEVEN PINKER
THE BETTER ANGELS OF OUR NATURE
WHY VIOLENCE HAS DECLINED

International Studies Quarterly (2006) **50**, 673–680

The Declining Risk of Death in Battle

BETHANY LACINA

Stanford University

NILS PETTER GLEDITSCH

Centre for the Study of Civil War, International Peace Research Institute

BRUCE RUSSETT

Yale University

A recent article using the new Correlates of War (COW) data on the distribution of interstate, intrastate, and extrastate wars from 1816 to 1997 claims there was a relatively constant risk of death in battle during that time. We show that the authors' information is skewed by irregularities in the COW deaths data, and contest their pessimistic interpretation. Using revised information on battle deaths from 1900 to 2002 we demonstrate that the risk of death in battle by no means followed a flat line, but rather declined significantly after World War II and again after the end of the Cold War. Future users should note that the deaths data collected for the three conflict types by COW are not comparable, and using them as such tends to underestimate the share of fatalities due to major interstate conflicts.

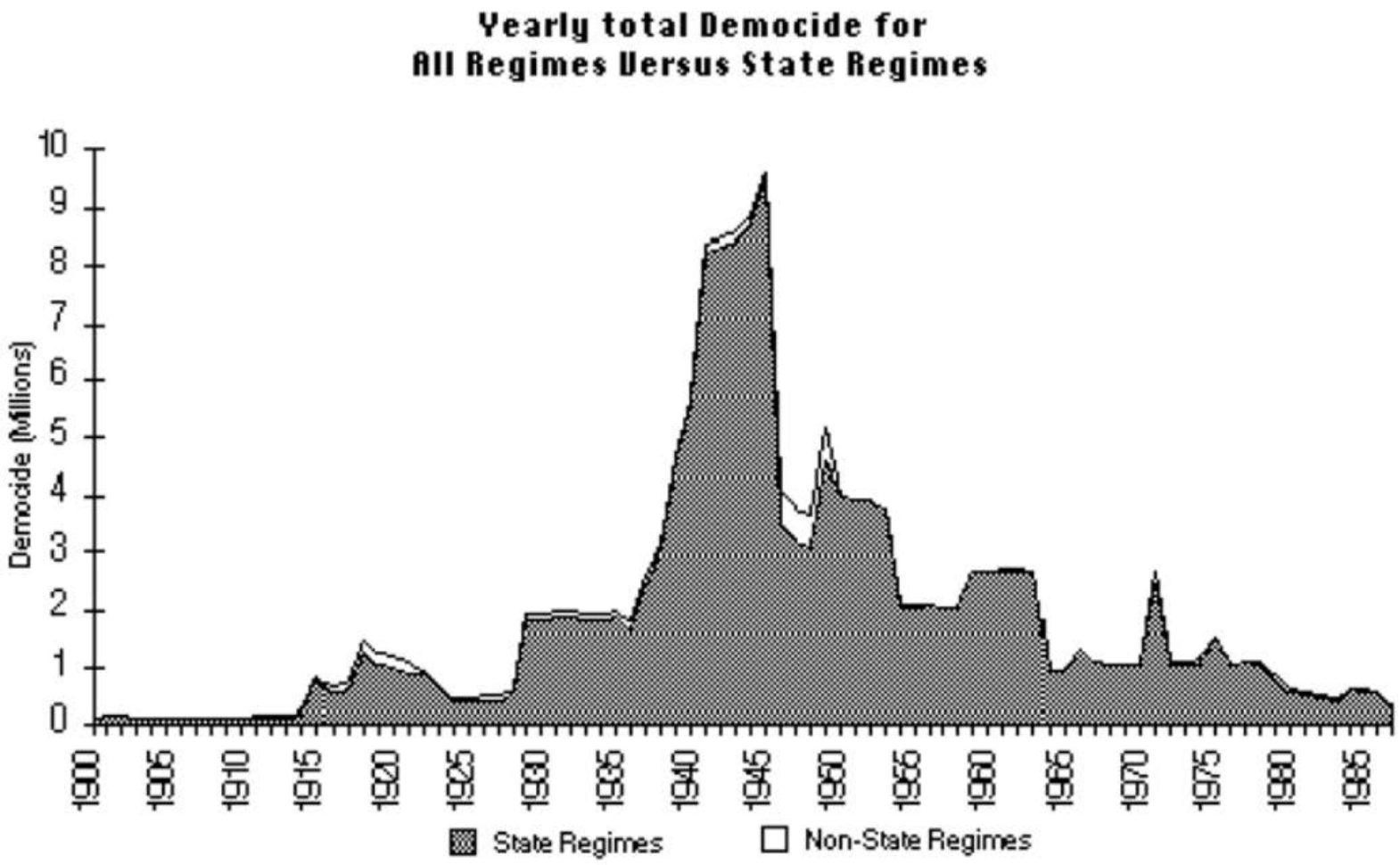
Yearly total Democide for
All Regimes Versus State Regimes
Democide (Millions)
10
9
8
7
6
5
4
3
2
1
0
1900
1905
1910
1915
1920
1925
1930
1935
1940
1945
1950
1955
1960
1965
1970
1975
1980
1985
State Regimes
Non-State Regimes

ORIGINAL ARTICLE

The Impact of Airbags and Seat Belts on the Incidence and Severity of Maxillofacial Injuries in Automobile Accidents in New York State

Jason Mouzakes, MD; Peter J. Koltai, MD; Siobhan Kuhar, MD, PhD; Dan S. Bernstein, MCP; Paul Wing, DEngin; Edward Salsberg, MPA

Objective: To evaluate the effect driver-side and passenger-side airbags have had on the incidence and severity of maxillofacial trauma in victims of automobile accidents.

Design: Retrospective analysis of all automobile (passenger cars and light trucks) accidents reported in 1994.

Setting: New York State.

Patients: Of the 595910 individuals involved in motor vehicle accidents in New York in 1994, 377054 individuals were initially selected from accidents involving cars and light trucks. Of this subset, 164238 drivers and 62755 right front passengers were selected for analysis.

Main Outcome Measures: Each case is described in a single record with approximately 100 variables describing the accident, eg, vehicle, safety equipment installed and utilized or deployed, occupant position, patient demographics, *International Classification of Diseases, Ninth Revision, Clinical Modification (ICD-9-CM)* diagnoses, and procedural treatments rendered. A maxillofacial trauma severity scale was devised, based on the *ICD-9-CM* diagnoses.

Results: Individuals using airbags and seat belts sustained facial injuries at a rate of 1 in 449, compared with a rate of 1 in 40 for individuals who did not use seat belts or airbags ($P<.001$). Those using airbags alone sustained facial injuries at the intermediate rate of 1 in 148, and victims using seat belts without airbags demonstrated an injury rate of 1 in 217 ($P<.001$).

Conclusion: Use of driver-side airbags, when combined with use of seat belts, has resulted in a decrease in the incidence and severity of maxillofacial trauma.

Arch Otolaryngol Head Neck Surg. 2001;127:1189-1193

Table 4. Cross-tabulation of Seat Belt Use by Facial Injury Controlling for Presence of Airbag

	No. (%)		Rate of Injury
	No Facial Injury	Facial Injury	
Drivers in Vehicles Without Airbags (n = 125 141)*			
Seat belt use			
No	9721 (97.6)	241 (2.4)	1/40
Yes	114 651 (99.5)	528 (0.5)	1/217
Drivers in Vehicles With Airbags (n = 39 097)†			
Seat belt use			
No	6205 (99.3)	42 (0.7)	1/148
Yes	32 777 (99.98)	73 (0.02)	1/449

*Pearson $\chi^2 = 755.2$; $P<.001$.
†Pearson $\chi^2 = 36.3$; $P<.001$.

AMERICAN JOURNAL OF PHYSICAL ANTHROPOLOGY 80:229–237 (198

Trauma, Degenerative Disease, and Other Pathologies Among the Gombe Chimpanzees

ROBERT JURMAIN
Department of Anthropology, San Jose State University, San Jose, California 95192

KEY WORDS *Pan troglodytes*, Skeletal pathologies, Fractures, Joint disease

ABSTRACT The well-known and extremely well-documented chimpanzees from Gombe National Park were analyzed for presence of skeletal pathologies. Of the 15 animals available for study, 11 were old and complete enough to permit systematic analysis. Of these, 10 showed some evidence of skeletal pathological involvement. The most common type of lesion seen resulted from trauma. Those chimps with the most fractures (Old Female, 3; Flo, 4; Hugo, 8) are consistently the oldest individuals in the sample. In addition to accidental falls, the most common cause of trauma was from interpersonal violence, resulting in bite wounds (see in two individuals) and fractures (see in three individuals). Conversely to trauma, degenerative disease was exceedingly rare in this population, found in no large intervertebral joints (N = 344) and only two major synovial joints (N = 186). In fact, the complete lack of osteophytosis, even in older individuals, stands in stark contrast to the situation seen in modern humans, perhaps in our species reflecting a biomechanical cost of bipedality.

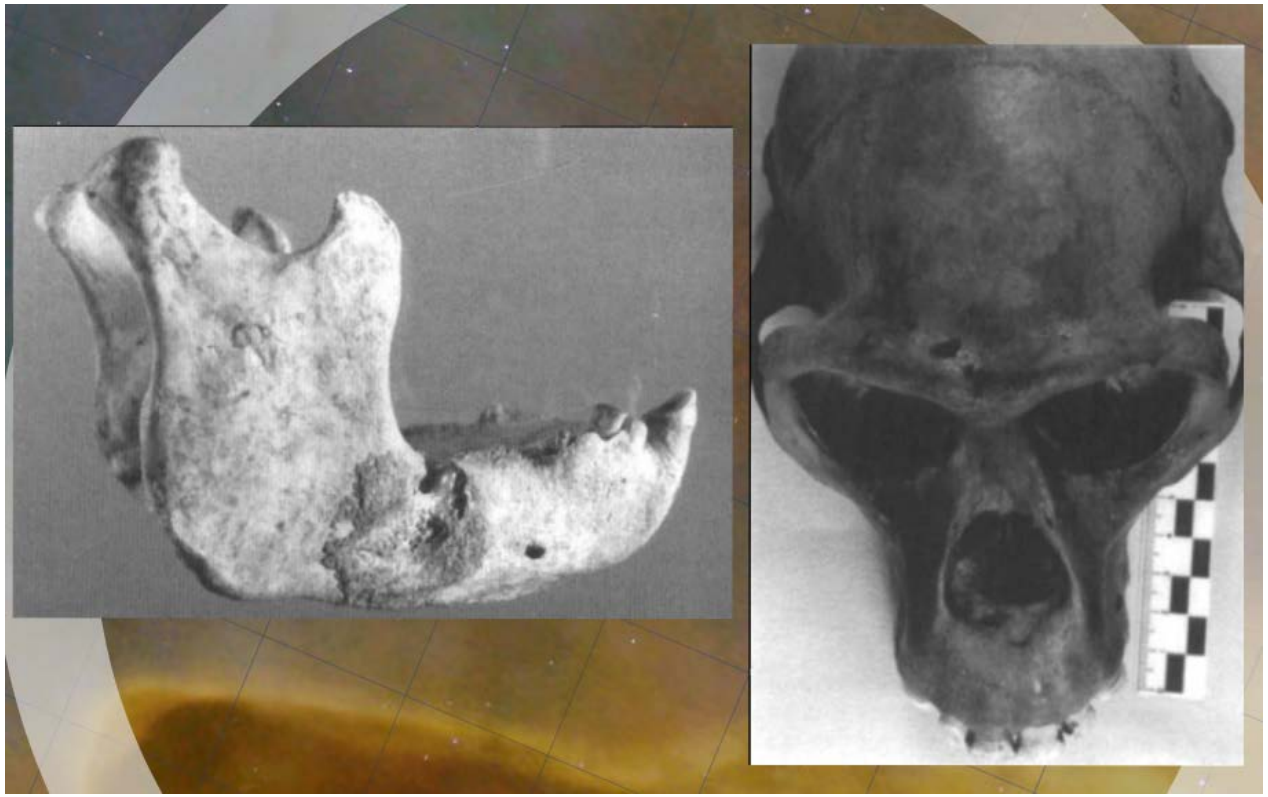

Maxillofacial Trauma

Deepak Krishnan DDS FACS

Oral Max-Fac Surgeon

Etiology

- @60% of patients - multisystem trauma and the potential for airway compromise.
  - 20-50% concurrent brain injury.
  - 1-4% cervical spine injuries.
  - Blindness occurs in 0.5-3%
- 25% of women with facial trauma -victims of domestic violence.
- 25% of patients with severe facial trauma - develop Post Traumatic Stress Disorder

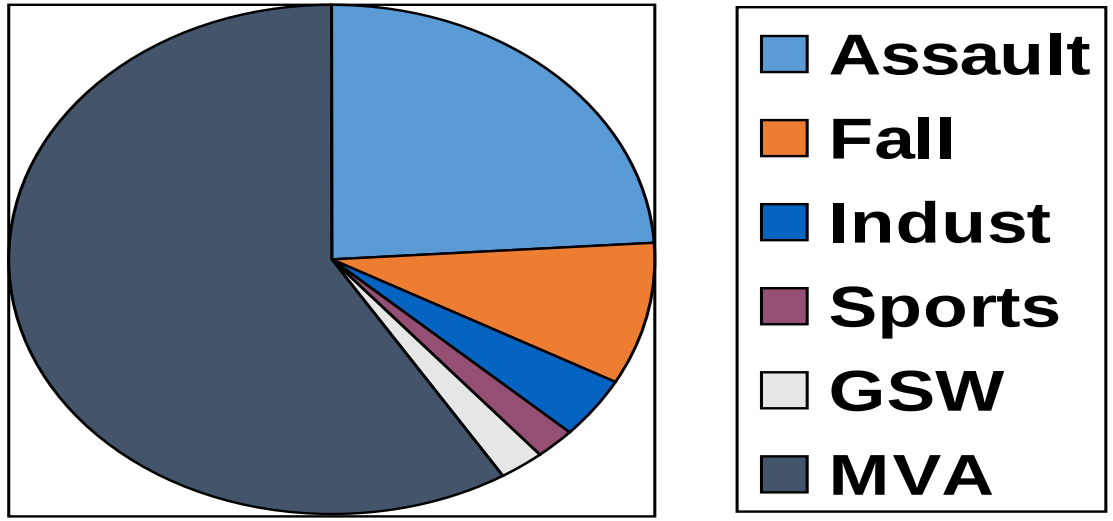

Fracture Forces

- High Impact:
  - Supraorbital rim – 200 G
  - Symphysis of the Mandible –100 G
  - Frontal – 100 G
  - Angle of the mandible – 70 G
- Low Impact:
  - Zygoma – 50 G
  - Nasal bone – 30 G

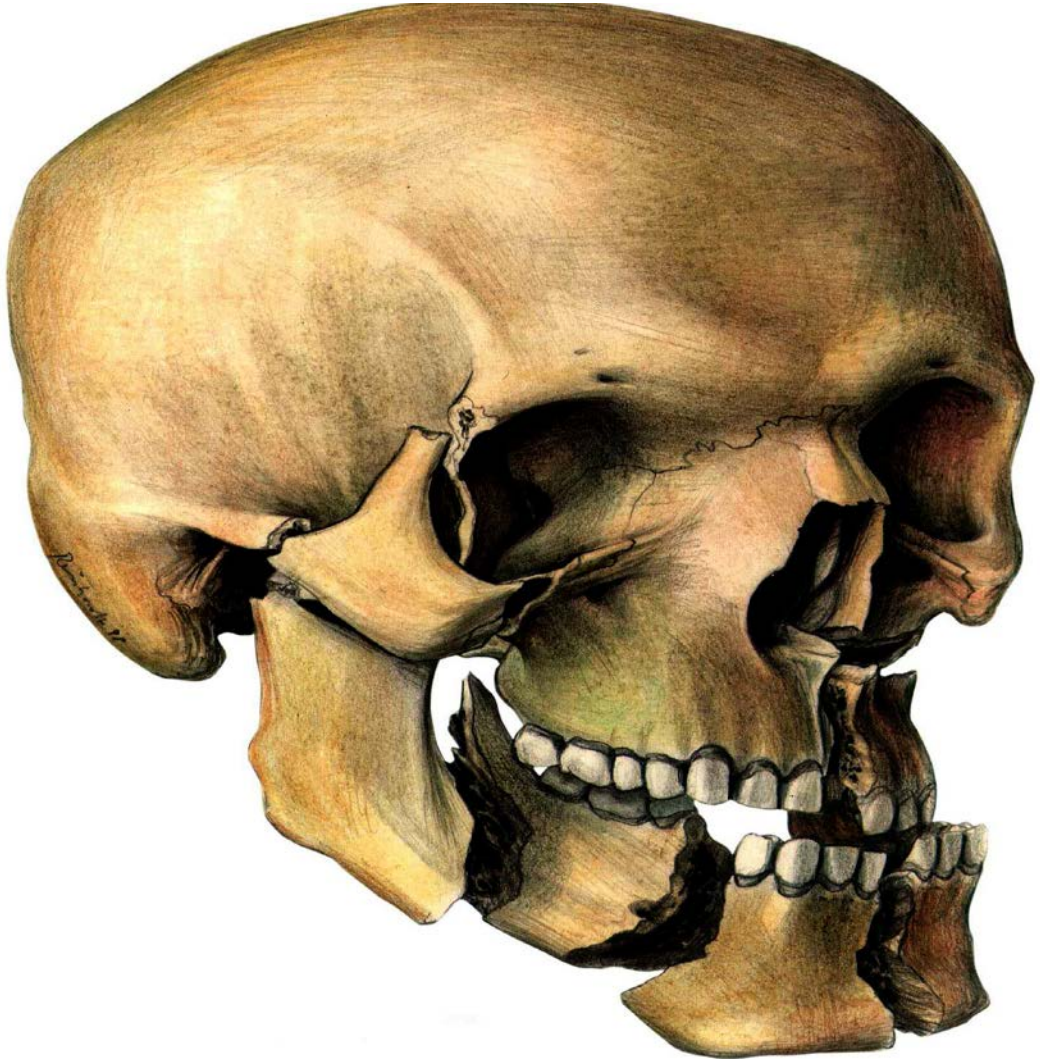

Facial Fractures classification

- Neuro-cranium and Frontal sinus fractures (anterior & posterior)
- Mid-facial fractures
  - Involve or effect occlusion
  - Individual anatomic region fractures with no occlusal involvement.
  - Zygoma (ZMC) fractures
  - Orbit fractures
  - Nasal fractures
  - Maxilla Fractures
- Composite fractures
- NOE – fractures
- Combination of different **Le Fort** fractures
- Avulsive and penetrating wounds
- High velocity blunt trauma
- Mandibular fractures

Rene Le Fort
1869 – 1951



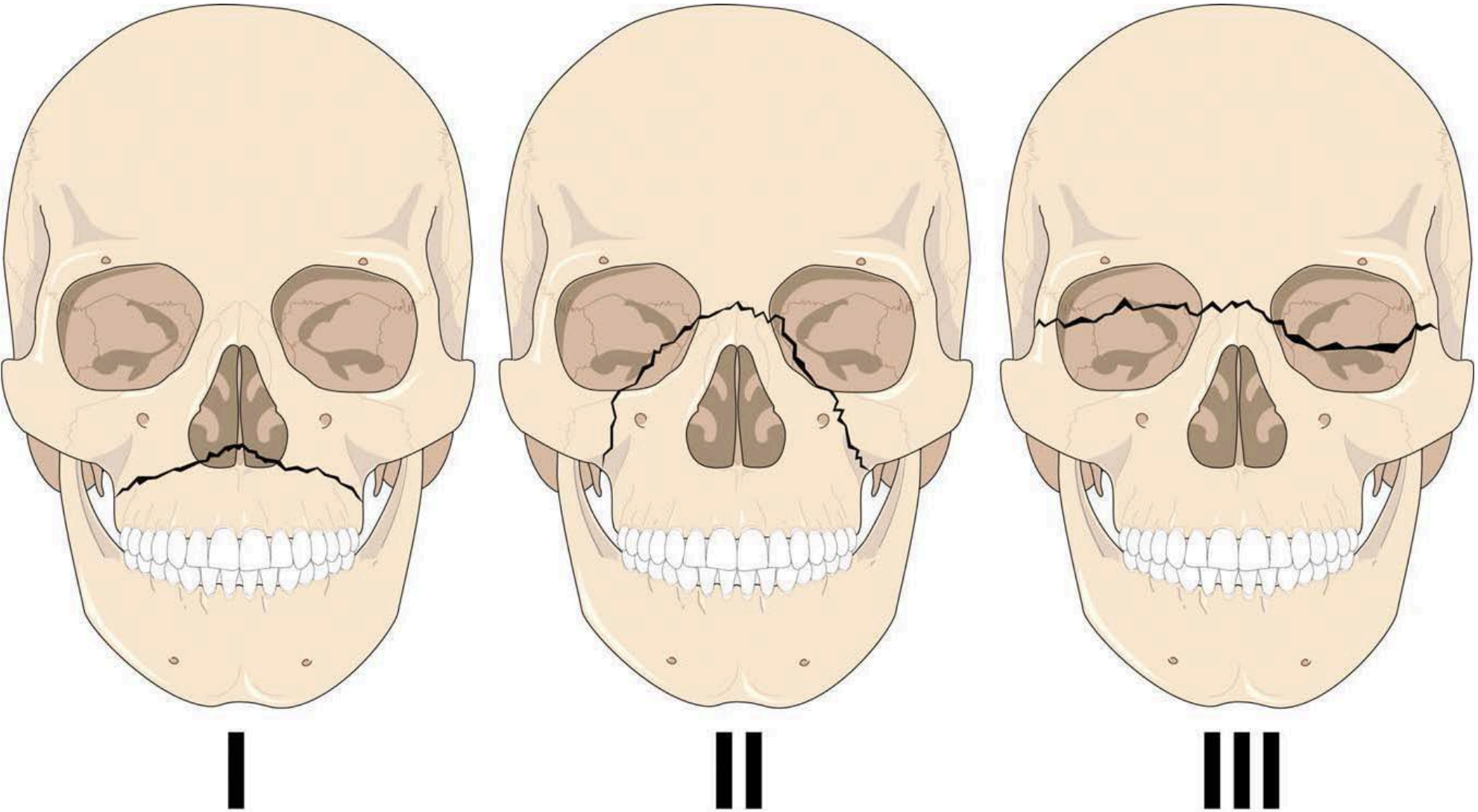
I
II
III

Skeletal Buttresses

- Horizontal buttress
  - H1: Supraorbital rim
  - H2: Infraorbital rim
  - H3: Palate
  - S1: Zygomatic Arch
  - Mandible (body/symphysis)
- Vertical buttress
  - V1: Nasomaxillary
  - V2: Zygomaticomaxillary
  - V3: Pterygomaxillary
  - Mandible (condyle/ramus

Management

- ATLS protocol
- Airway management in Maxillofacial Trauma, Laryngo-tracheal injuries
- Bony injuries
- Soft tissue injuries

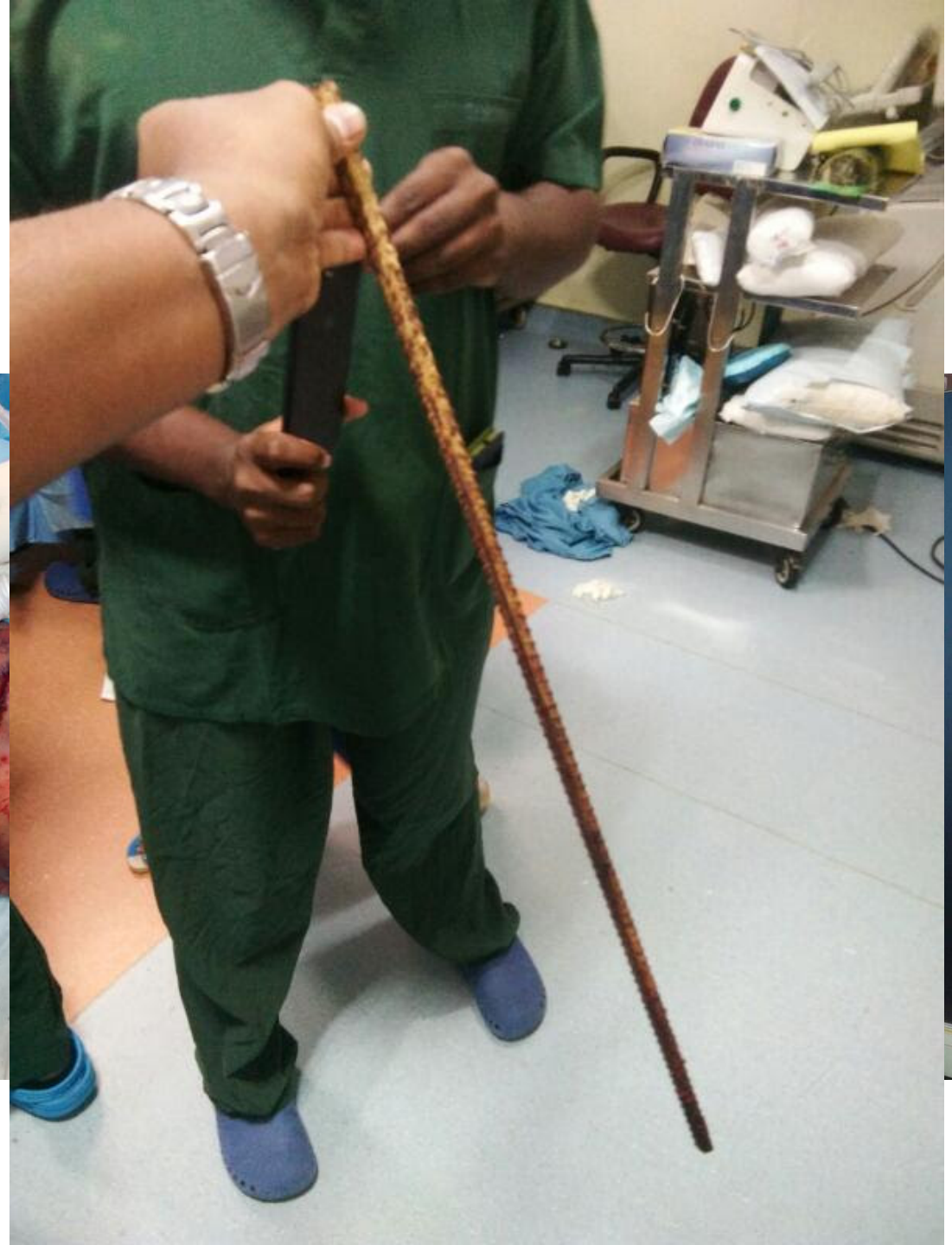

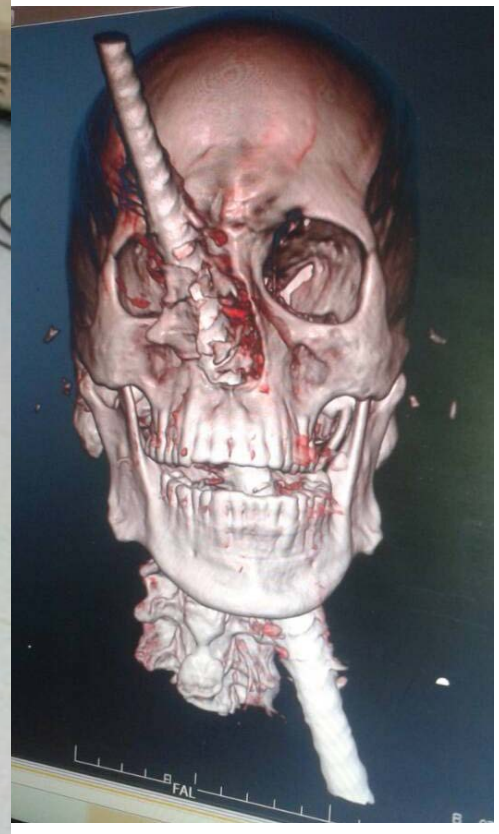
FAL

Physical Examination

- Check visual acuity
- Check pupils for roundness and reactivity
- Examine the eyelids for lacerations
- Test extra ocular muscles
- Palpate around the entire orbits

Imaging

- Facial films
- Facial CT
- Panorex
- CBCT

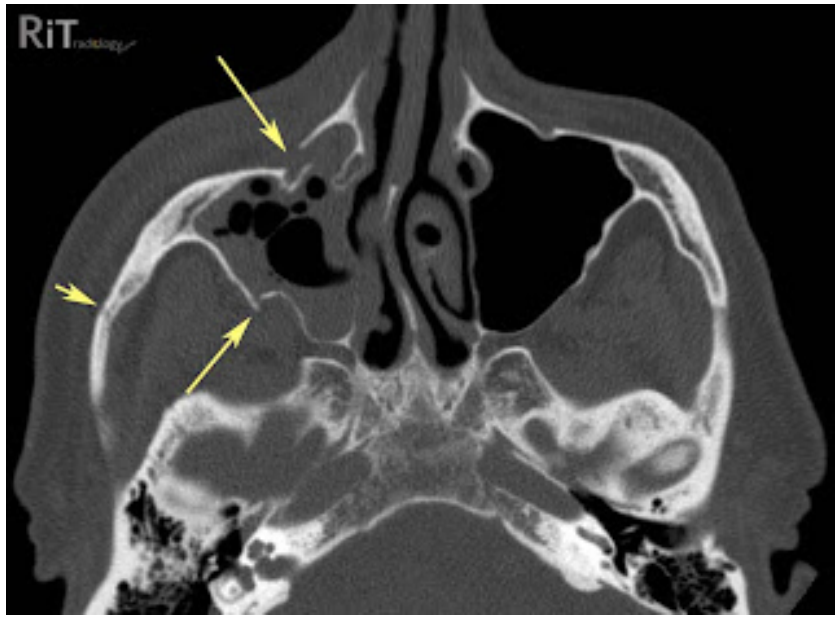

Management

- Where do we start
- When to treat
- How to treat
- Airway considerations
- Approaches

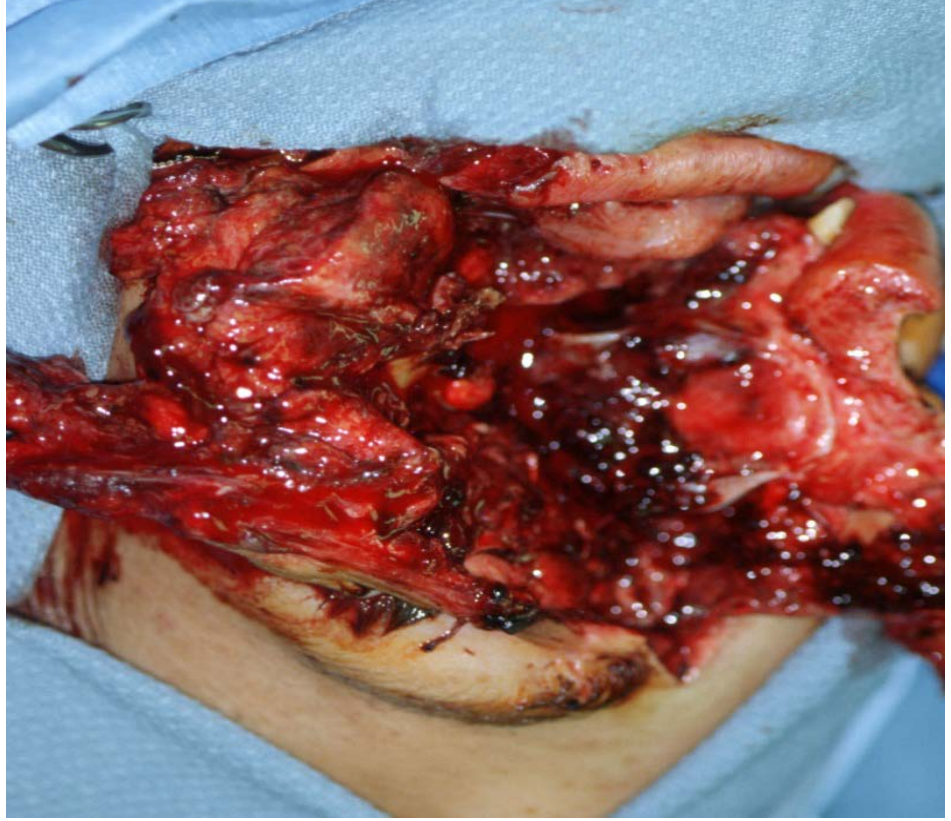

Assessment

Evaluation

- Vessels
  - Internal Carotid Artery
  - Vertebral Artery
  - Intra cranial vessels
  - Internal maxillary artery
- Bone :
  - Fractures
- Muscles

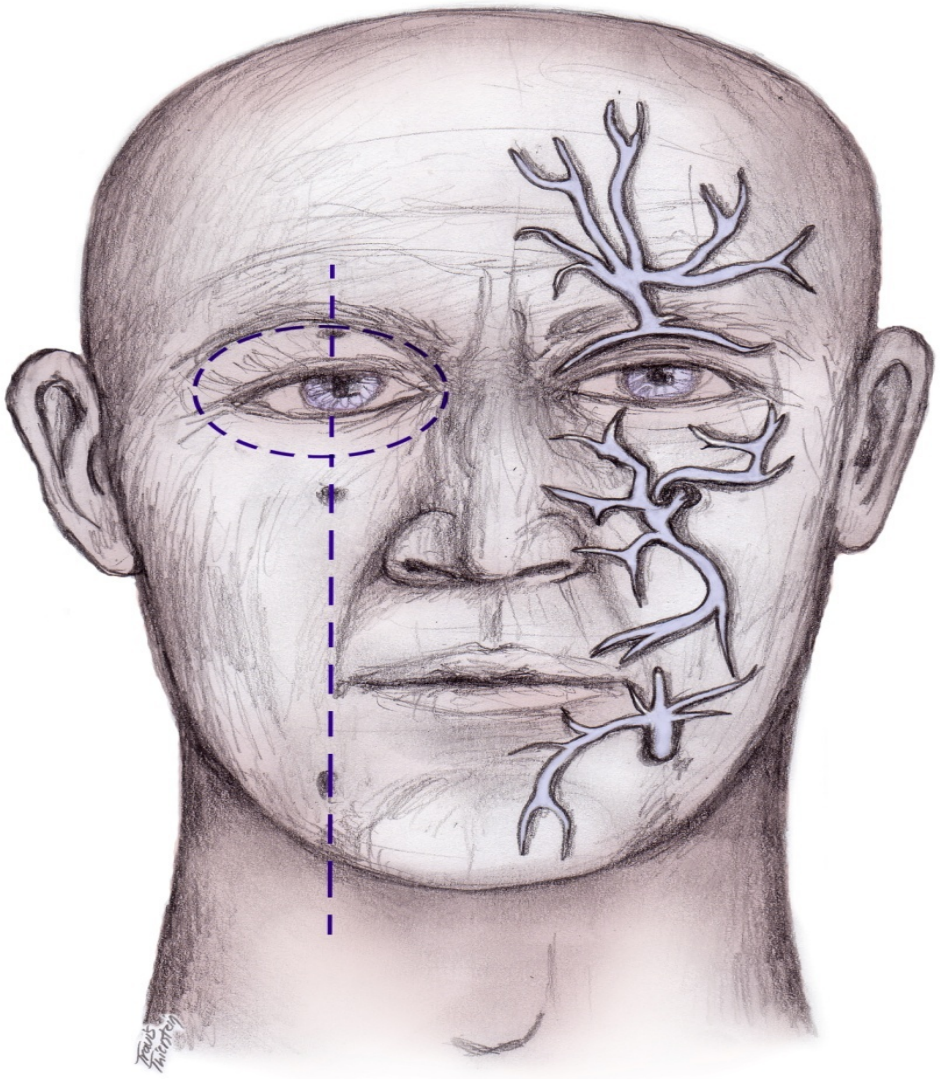

Assessment

- Ducts
  - Submandibular – rarely dysfunction
- Glands
  - Parotid
  - Lacrimal
- Nerves
    - CN V
    - CN VII

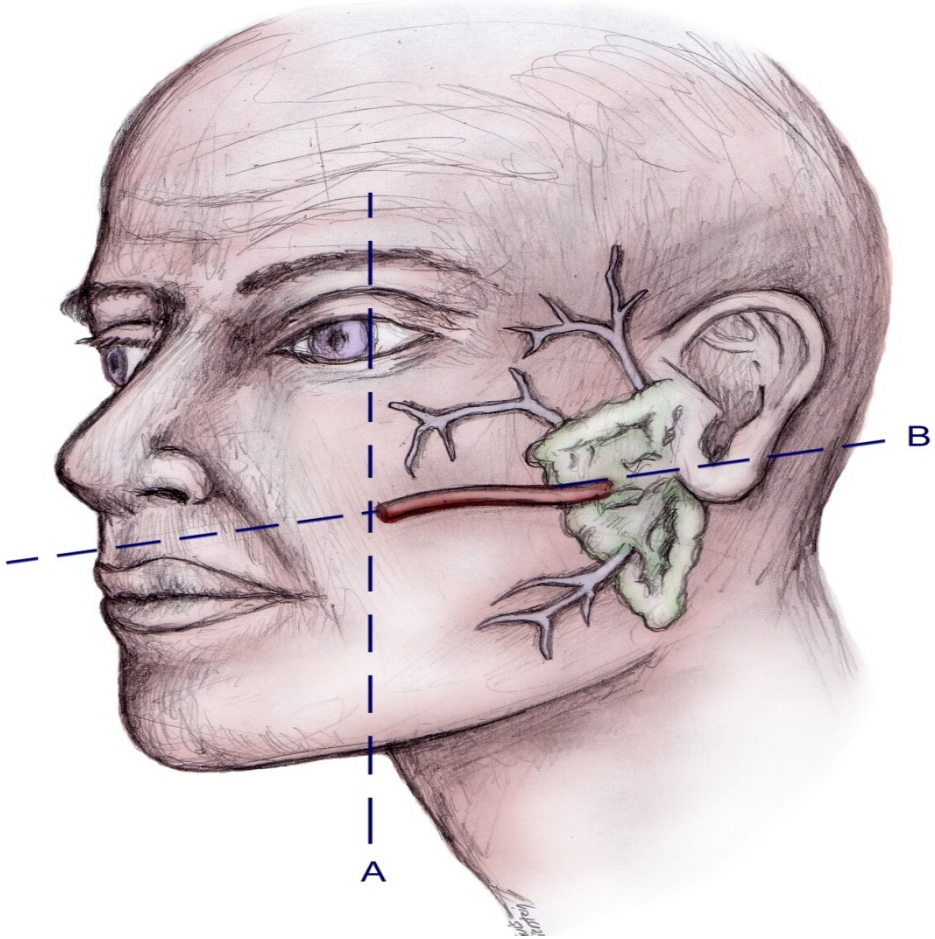

Approaches

- Facial approaches
  - Eyelid
  - Eyebrow
  - Preauricular
  - Retromandibular
  - Submandibular
- Intra-oral approaches

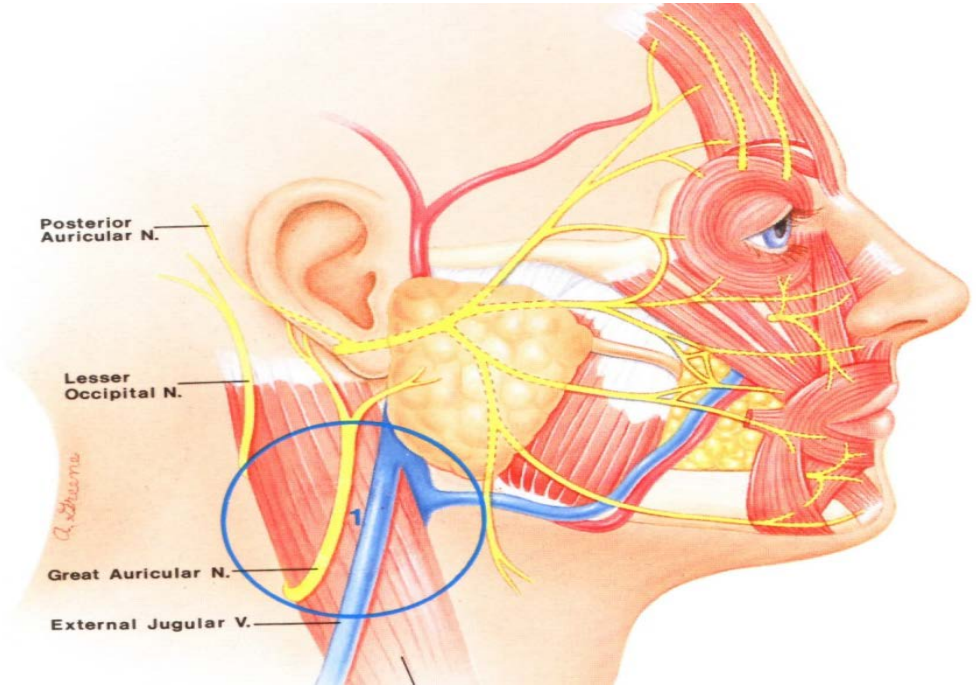

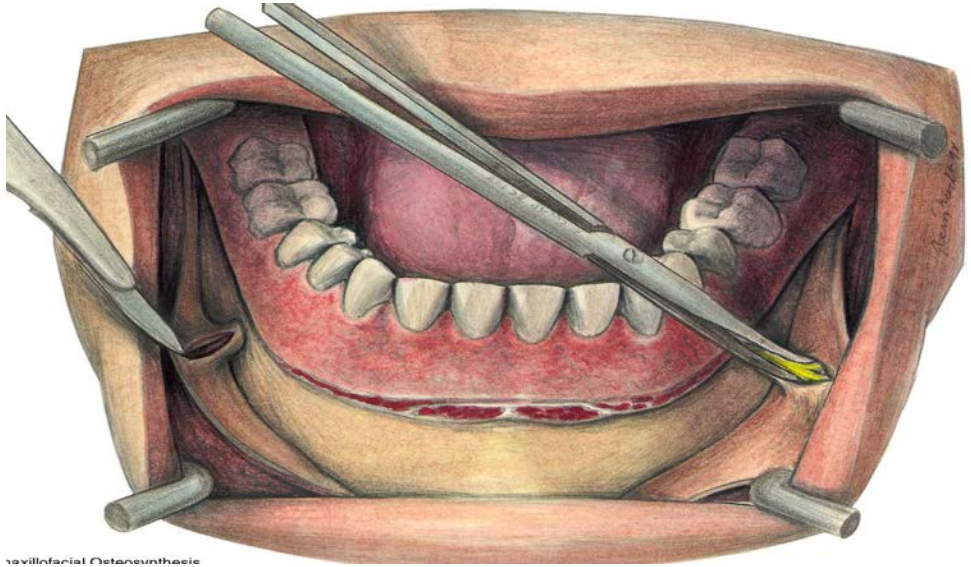

Frontal Sinus/ Bone Fractures

- Results from a direct blow to the frontal bone with blunt object
- Disruption or crepitance orbital rim
- Subcutaneous emphysema
- Associated with a laceration
- Associated with:
  - Intracranial injuries
  - Injuries to the orbital roof
  - Dural tears

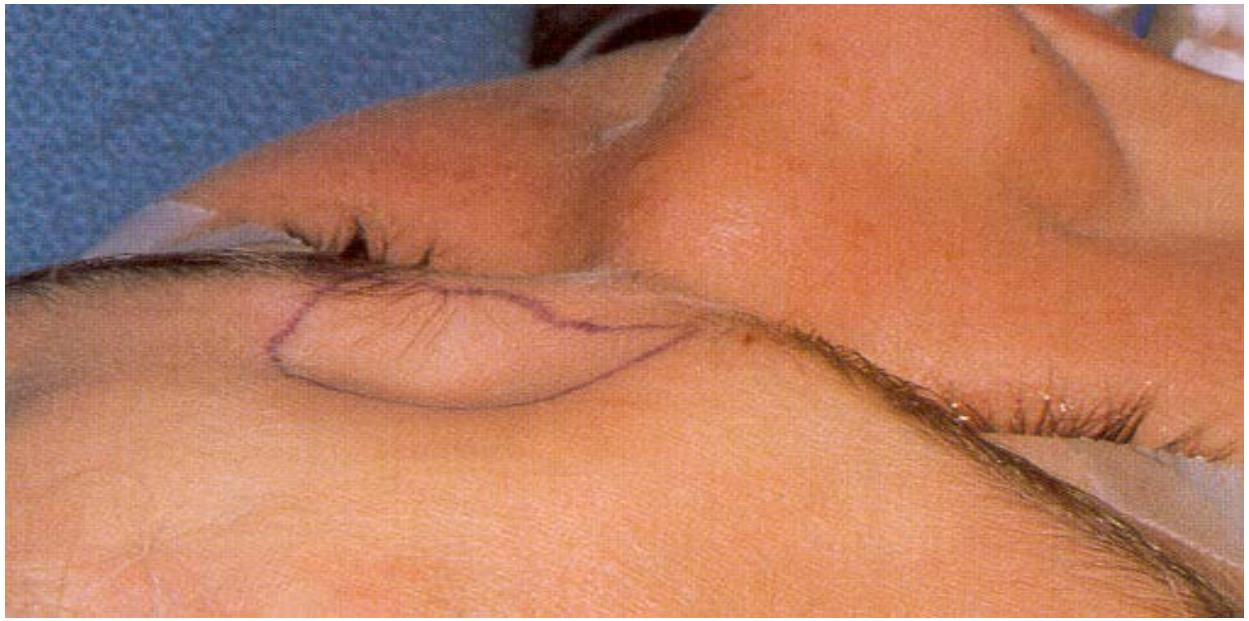

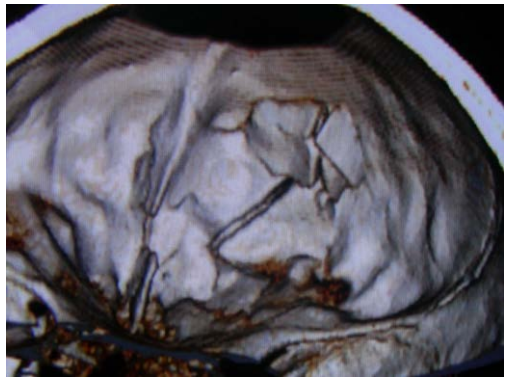

Frontal sinus fractures

- Classification
  - Anterior
  - Posterior
  - Both
- Cerebrospinal fluid more commonly in younger children due to the involvement of posterior sinus wall
- Naso-frontal duct involvement

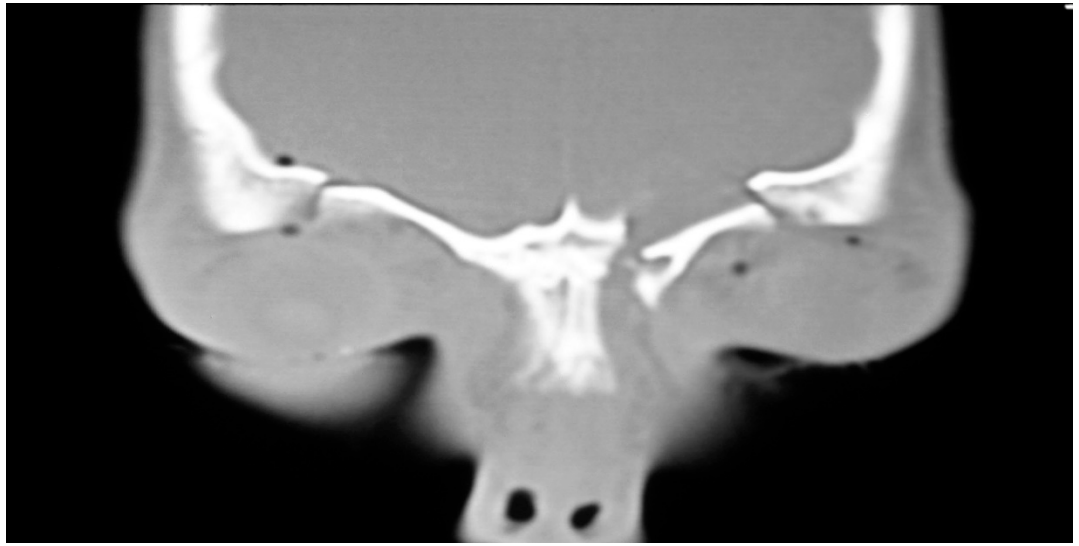

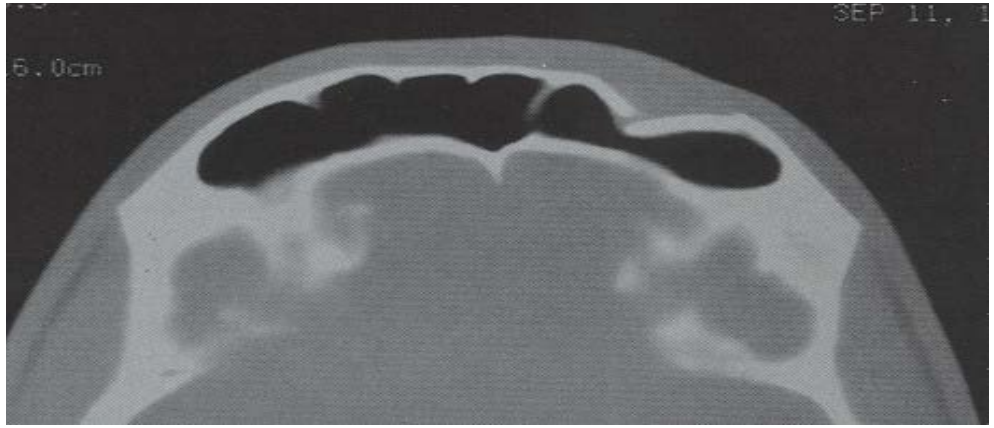

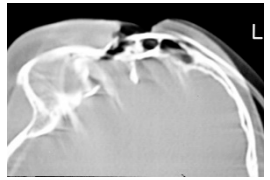

Associated Injuries In Frontal Sinus Fractures, Rodriguez E, et al.

INJURY	Without NFOT injury (%)	With NFOT injury (%)
Brain	31	76
Cervical spine	7	14
Upper Extremity Fracture	15	25
Lower Extremity Fracture	13	23
Pneumothorax	12	24
Abdominal	7	13

Associated Injuries In Frontal Sinus Fractures, Rodriguez E, et al.

INJURY	Without NFOT injury (%)	With NFOT injury (%)
Orbital roof	15	40
Orbital wall	7	15
Orbital floor	2	7
NOE	12	15
Zygoma	8	18
LeFort	2	17
Mandible	3	5

Goals of Treatment

- Prevent potential complications
- Isolate the intracranial contents from the sinus and nasal cavities
- Reestablish or eliminate the drainage system
- Restoration of normal frontal contour

Surgical Access

- Existing lacerations:
  - for limited injuries
  - extending it for access can further worsen aesthetics

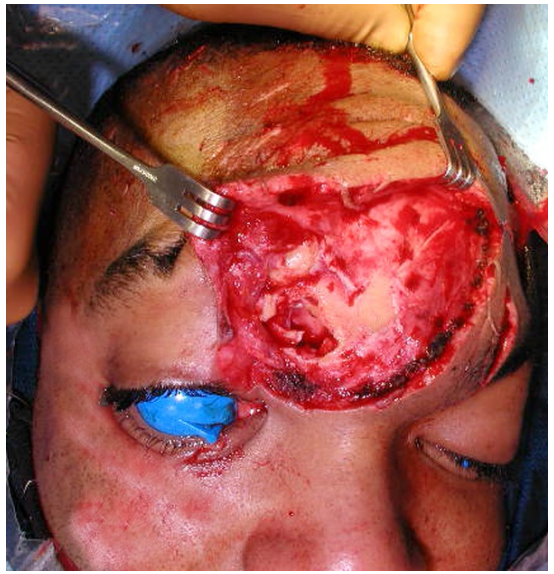


27
28 cm
Mallinckrodt, Inc.

Endoscopic Management of Frontal Sinus Fractures: Approaches

- Existing laceration
- Browlift approaches
- Transnasally
- 1 cm trephine incision under eyebrow, 5mm bur hole
- 2.7mm, 30° and 70° endoscopes used

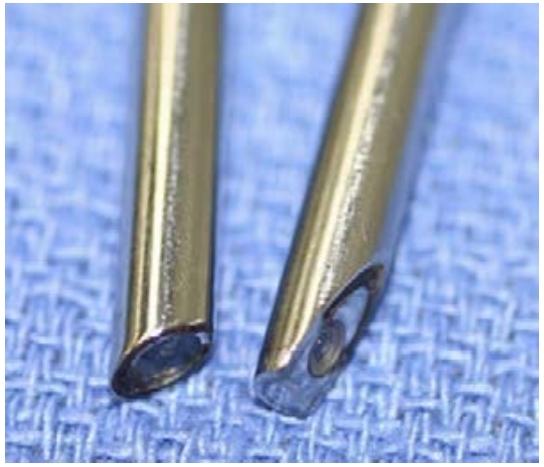

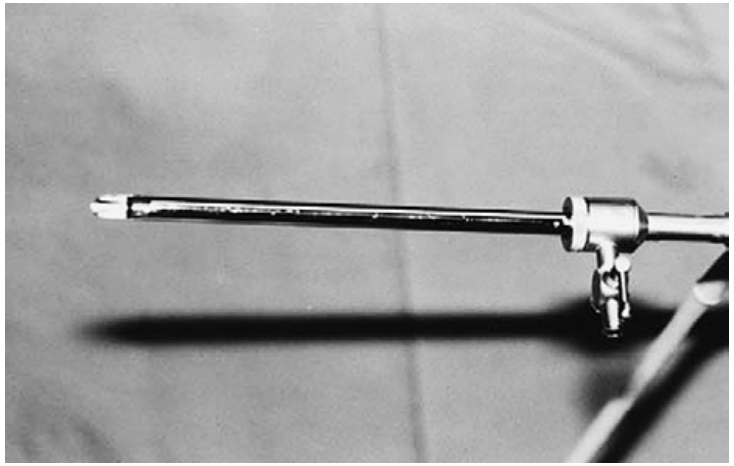

Suggested Criteria for Endoscopic Reduction of Frontal Fractures

- Posteriorly displaced anterior table fractures
- Wide anterior-posterior diameter of the frontal sinus and recess
- Intact posterior frontal sinus table
- Recent history of trauma

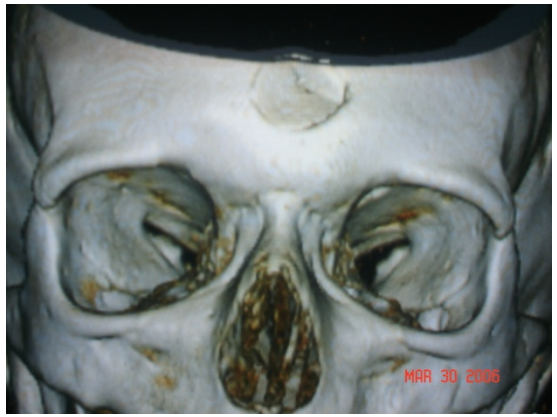

Treatment

- Patients with depressed skull fractures or with posterior wall involvement
  - Neurosurgery consultation

- Patients with isolated anterior wall fractures, non-displaced fractures can be treated outpatient after consultation with neurosurgery

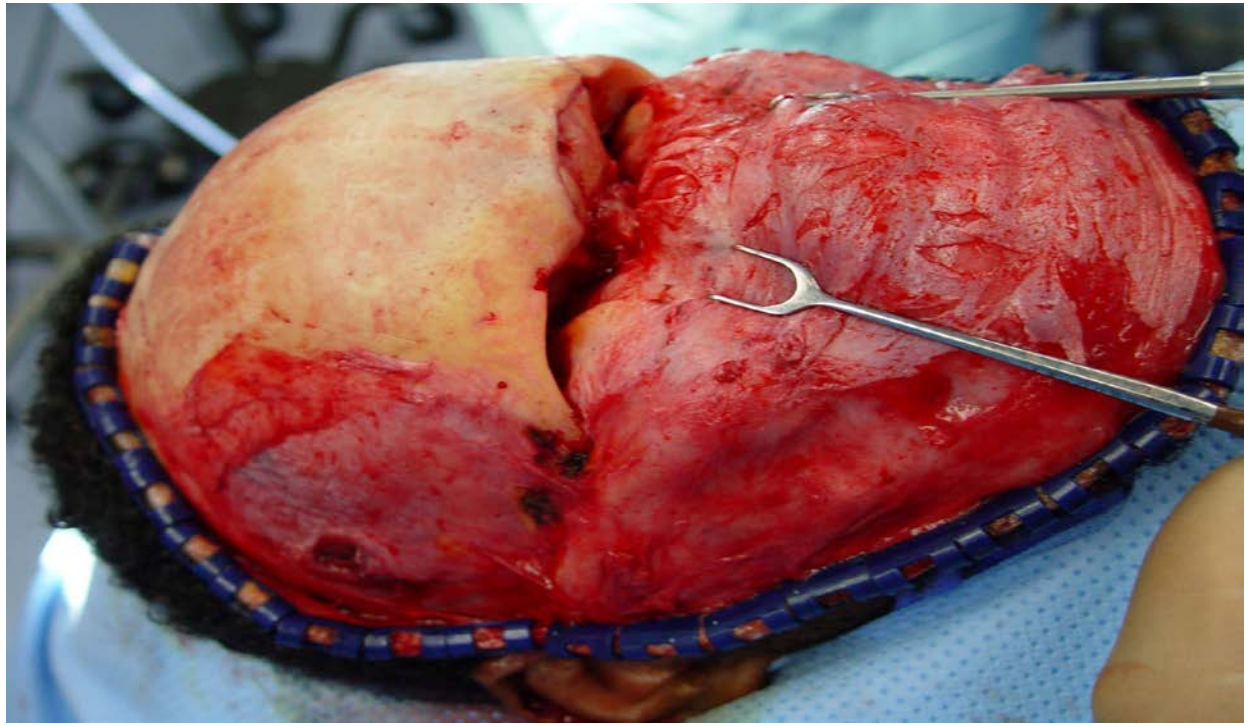

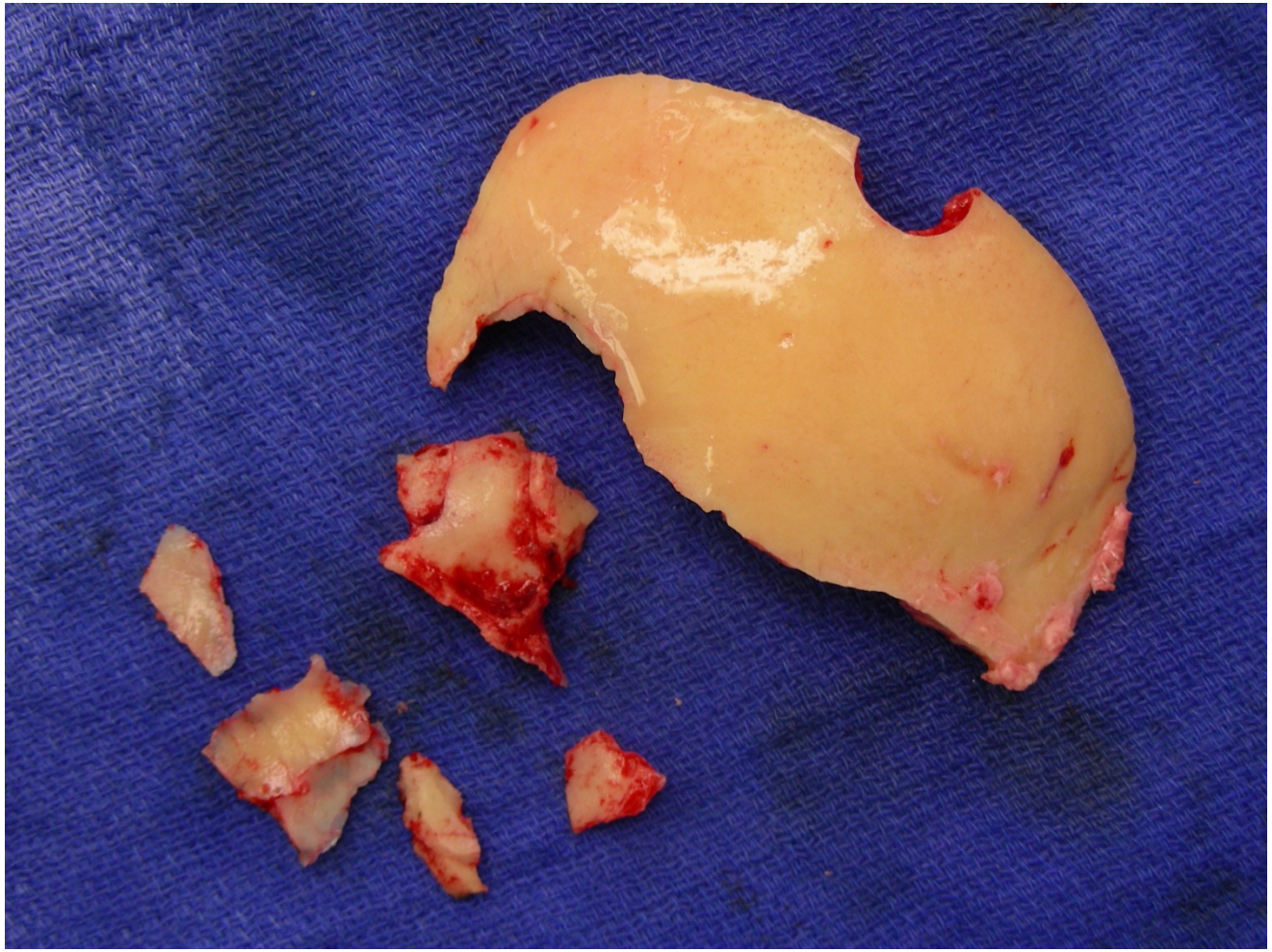

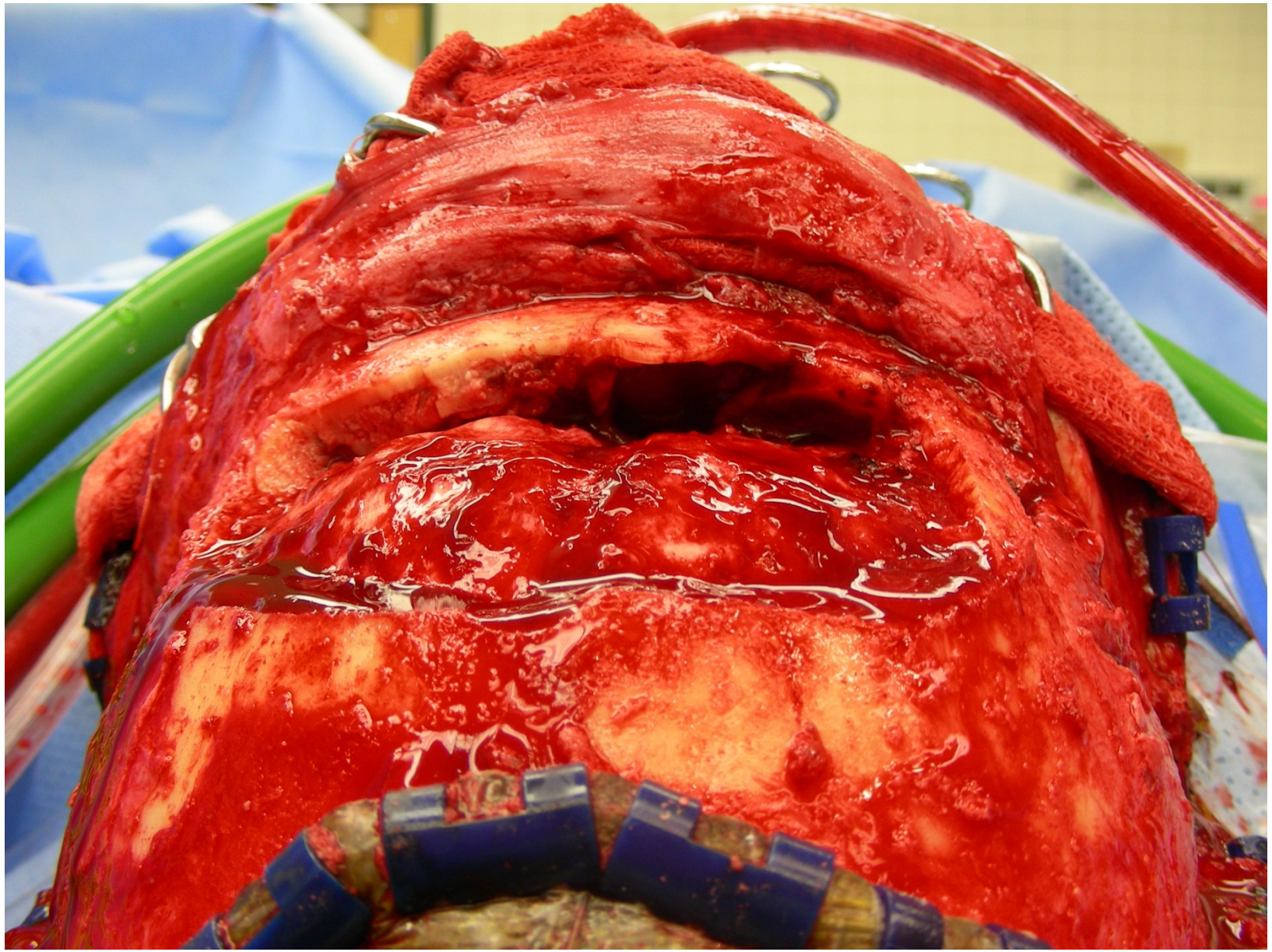

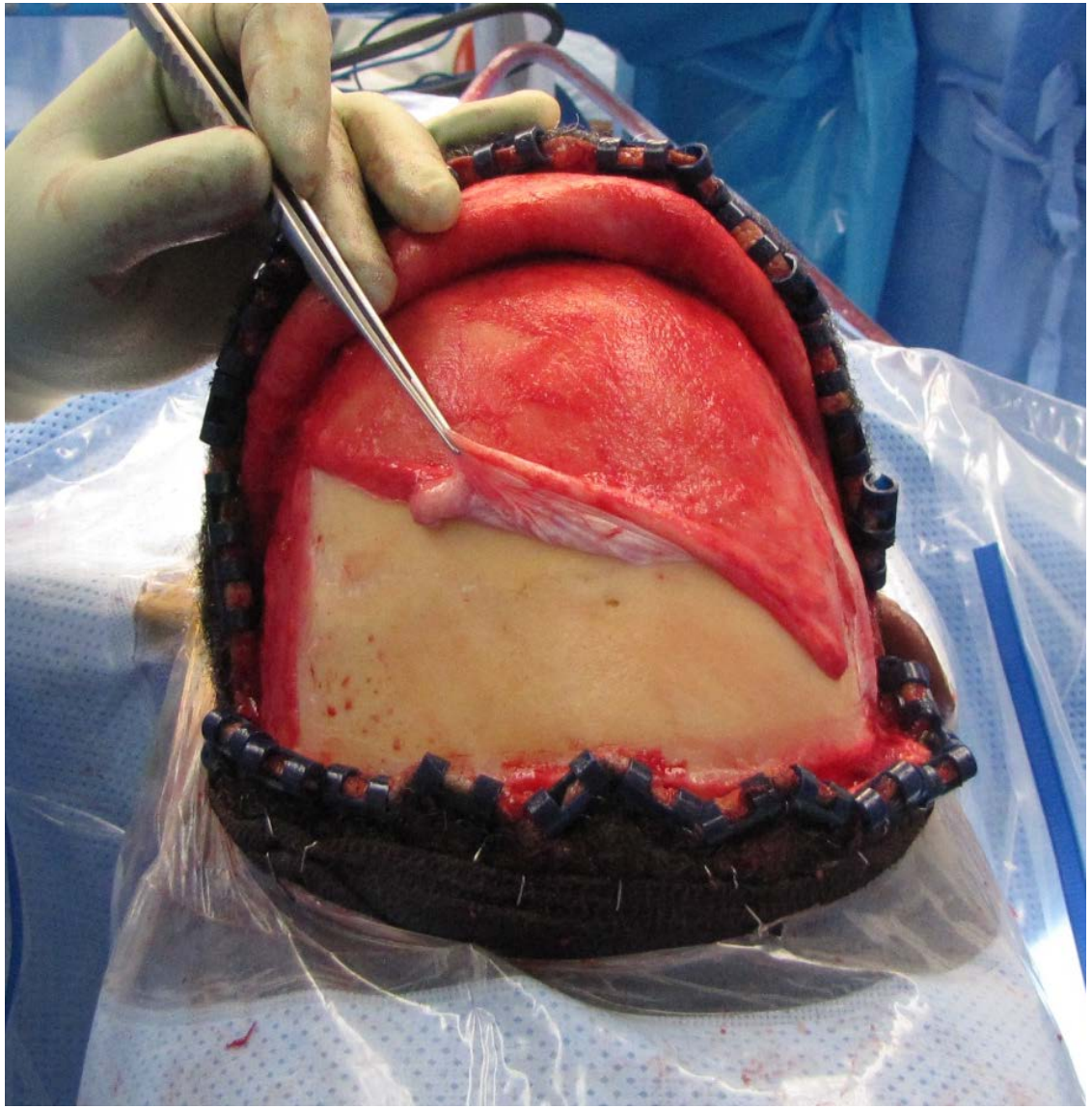

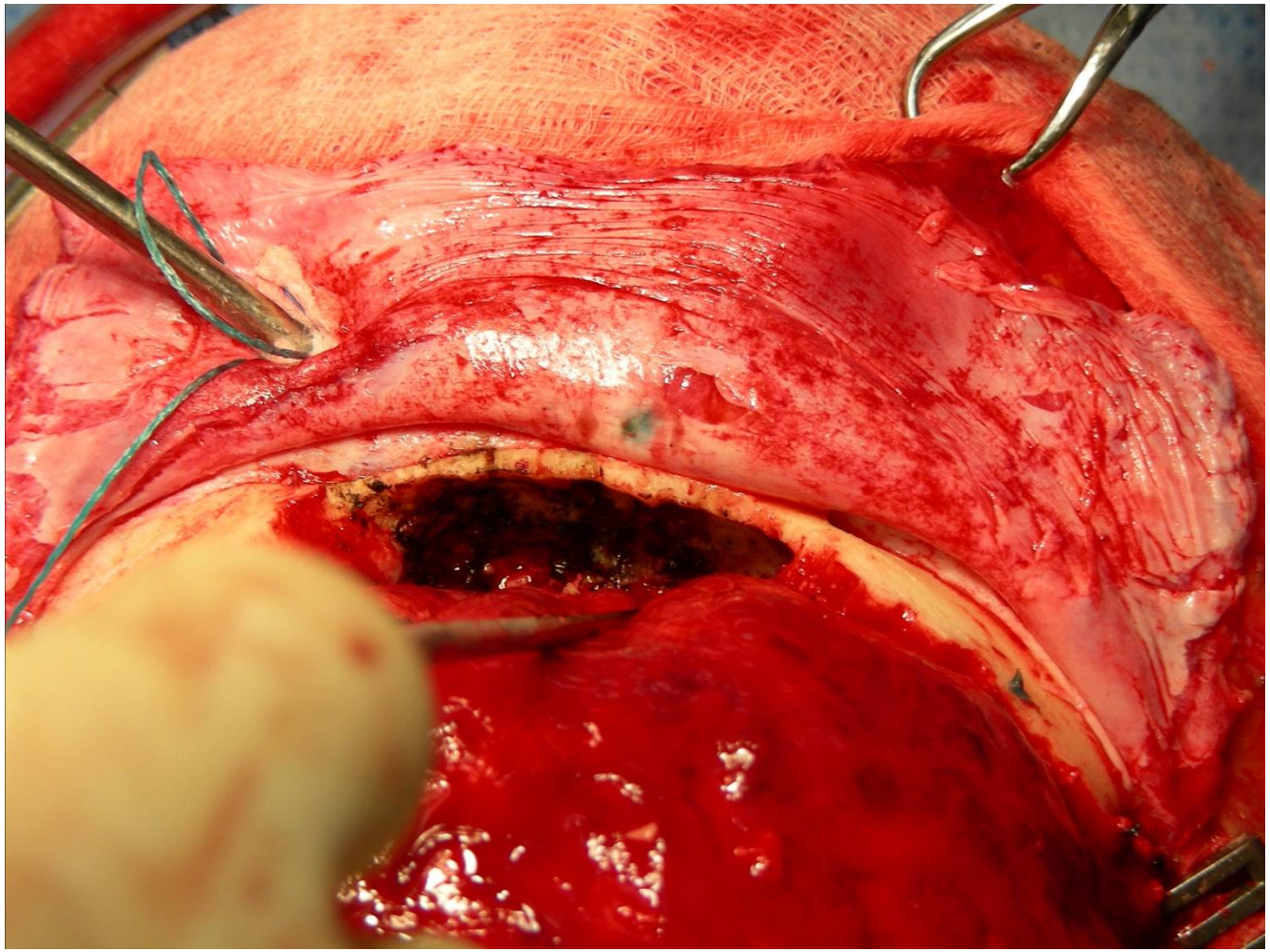

Evaluation of NFD Patency

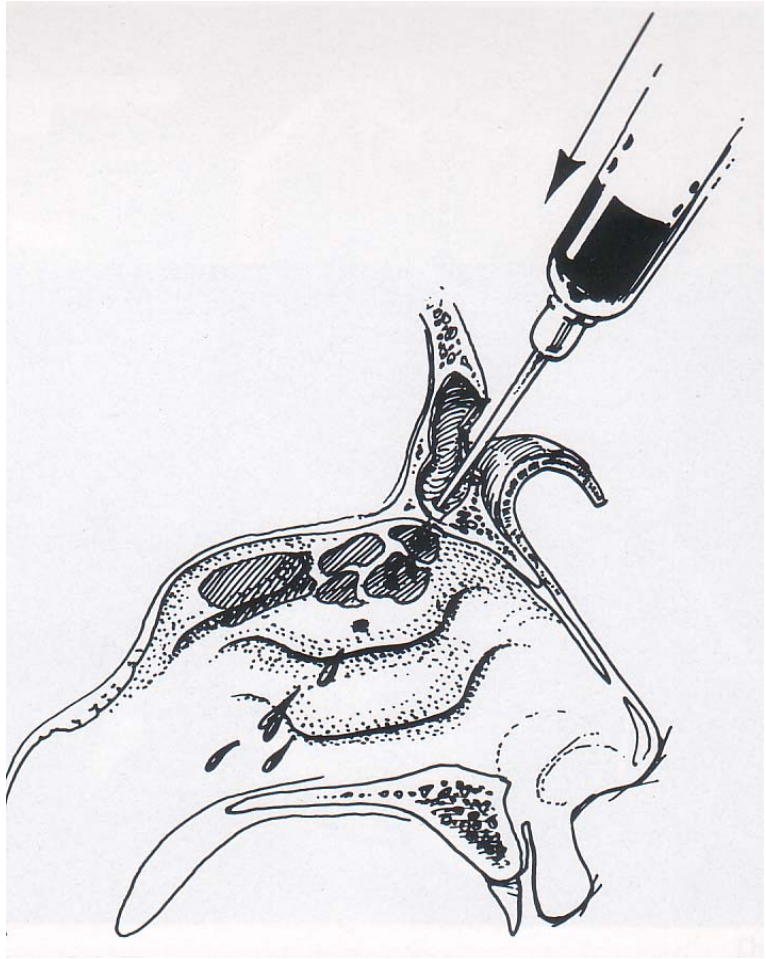

- Open exploration is the only sure method
- Methylene blue, indigo carmine, lipiodol (requires C-arm fluoroscopy), fluorescein (requires UV light source)

Materials/Methods Used In Obliteration

Autogenous:

- Autologous fat
- Autologous muscle
- Cancellous bone
- Spontaneous osteoneogenesis
- Pedicled flap

Alloplastic materials:

- HA
- Bioactive glass
- Methylmethacrylate
- Calcium phosphate bone cement
- Oxidized regenerated cellulose

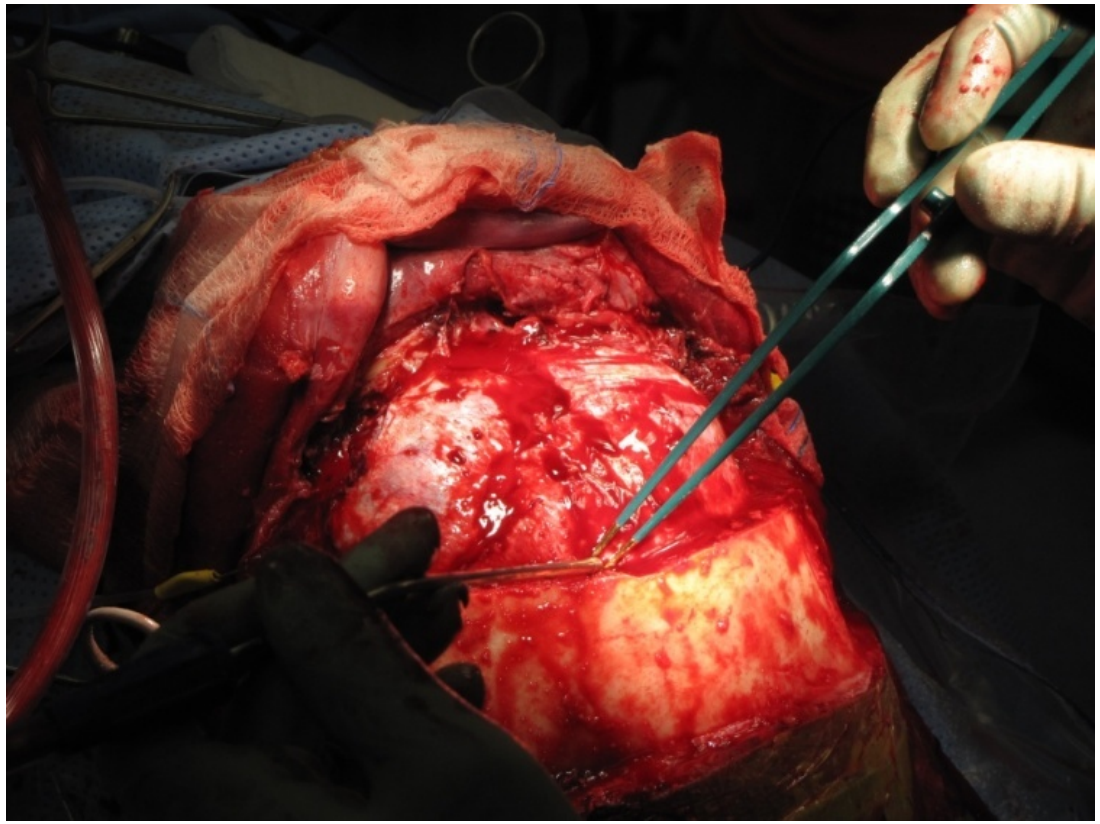


STAINLESS

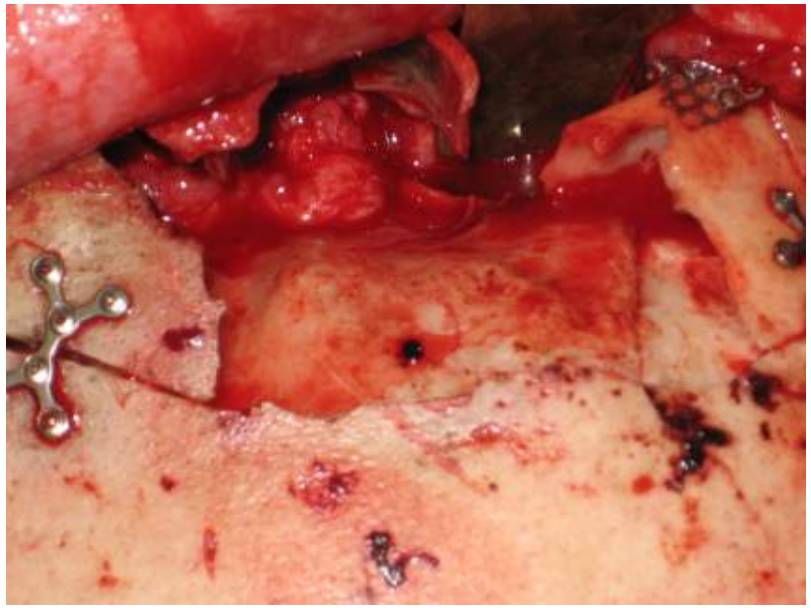

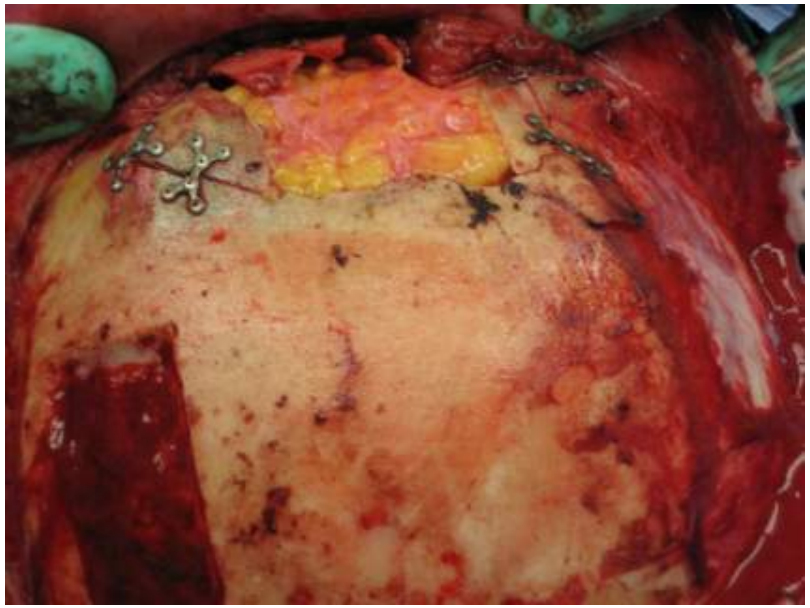

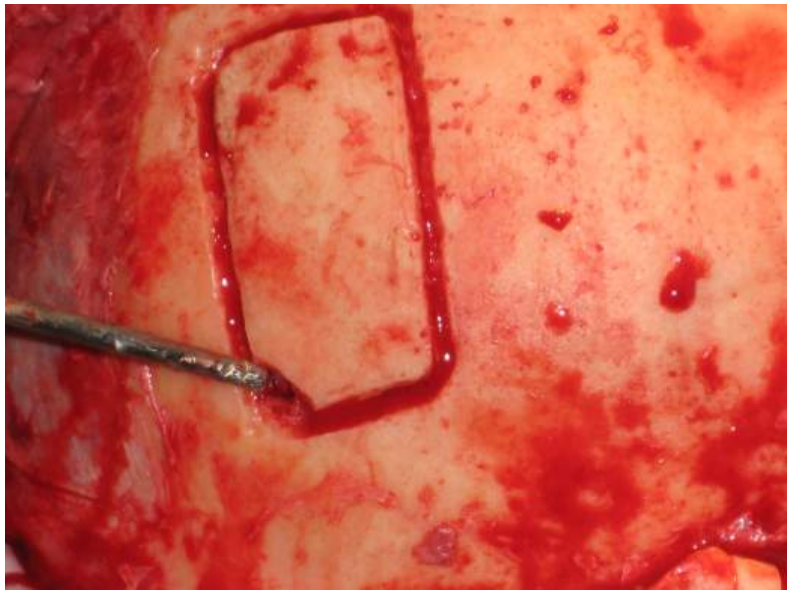

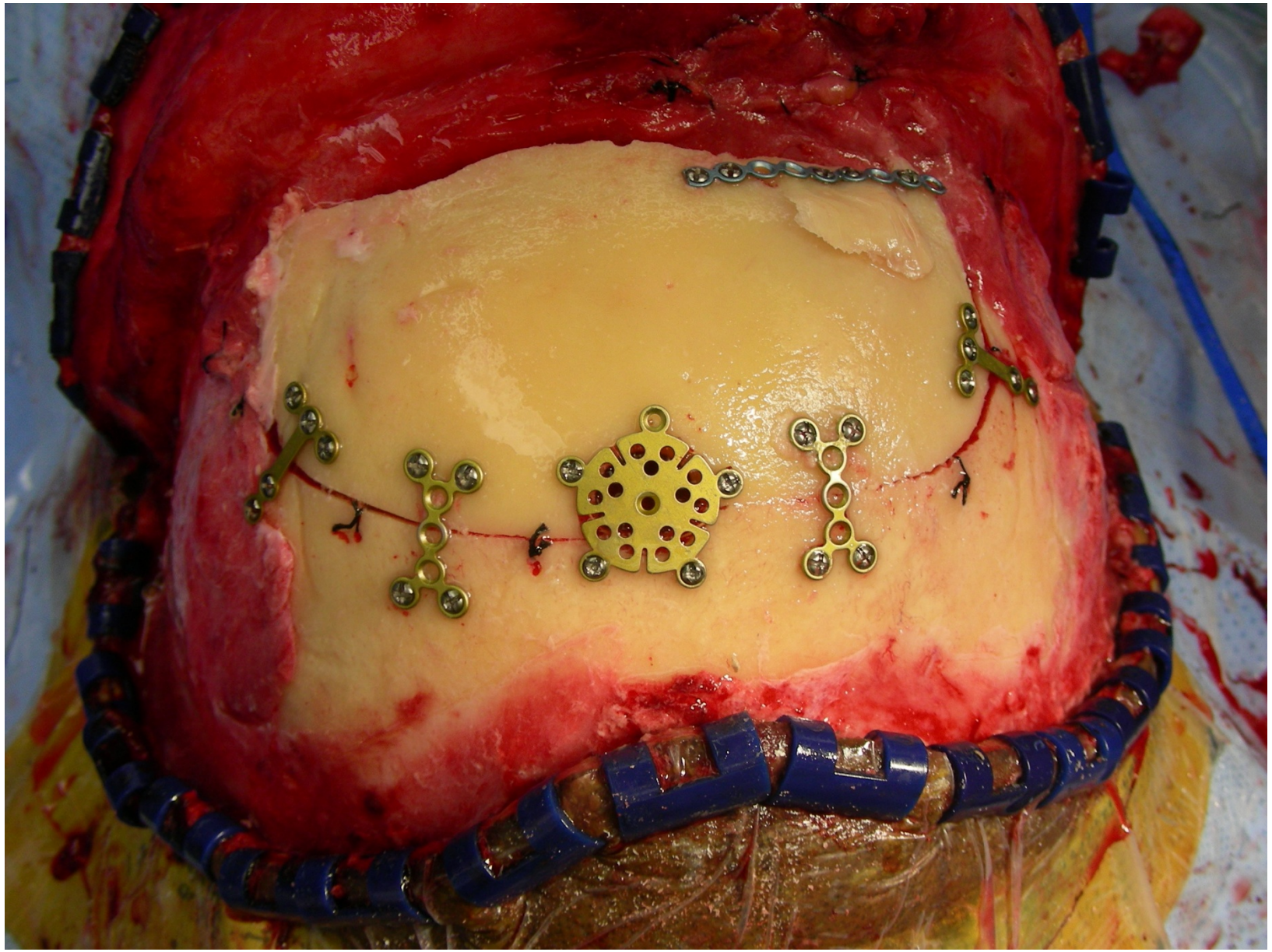

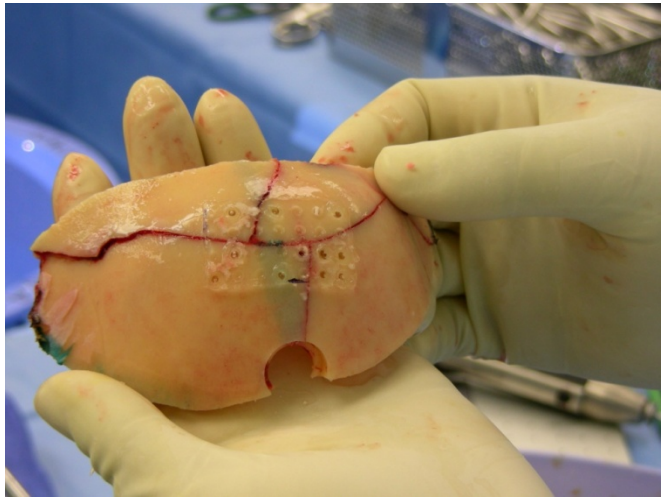

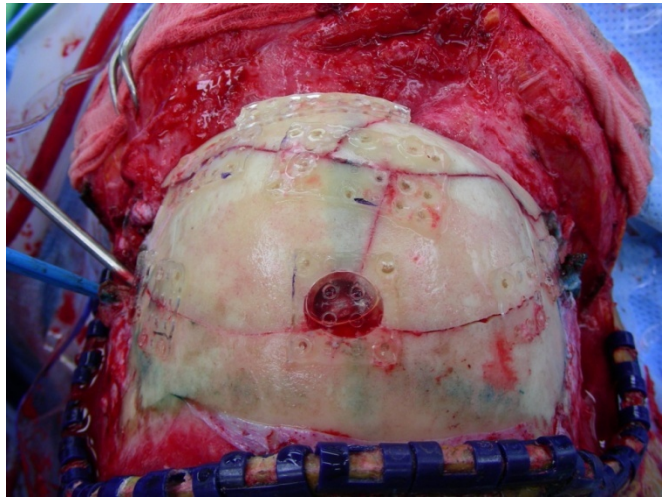




10 cm

A protocol for the management of frontal sinus fractures emphasizing sinus preservation. Bell RB et al. J Oral Maxillofac Surg 65:825-39, 2007

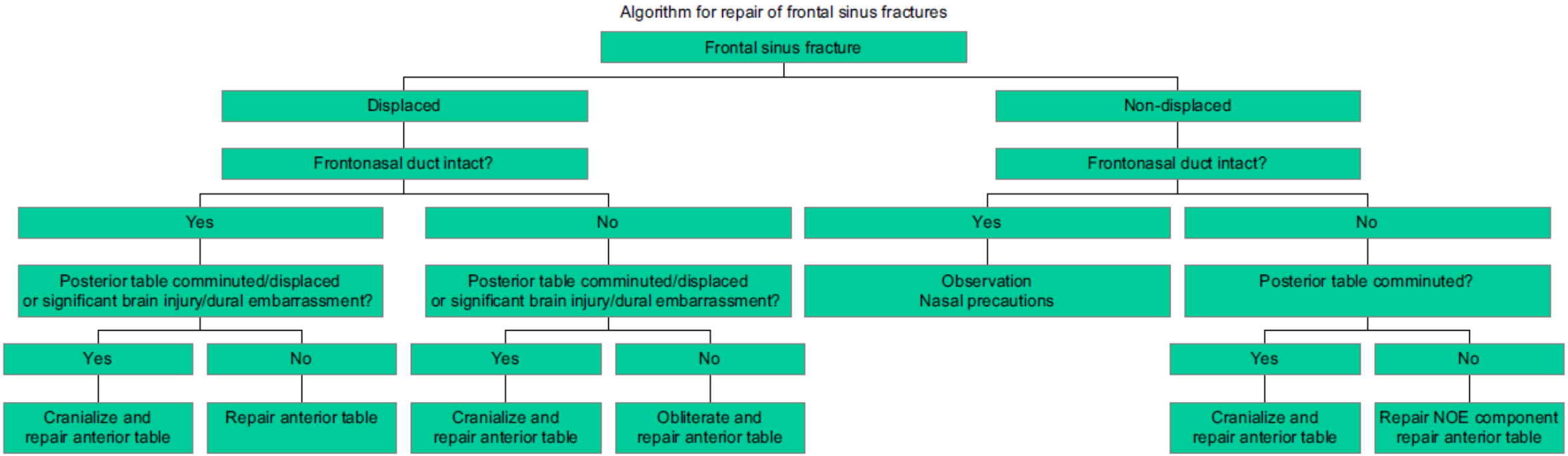

Why Is Management Controversial?

- Difficult to obtain a significant number of cases
- Follow-up time lengthy
  - complications may take years to develop
  - large subset of patients with poor follow-up
- Difficulties in comparing different types of fractures
- Lack of treatment uniformity
- Lack of statistical significance

26 year experience treating frontal sinus fractures: a novel algorithm based on anatomical fracture pattern and failure of conventional techniques. Rodriguez E, et al. Plast Recon Surg 122:1850-66, 2008.

- 857 patients
- 504 (58.8%) underwent surgery
- 10.4 % complication rate
- 353 observed
- 3.1 % complication rate
- All complications involved naso-frontal tract injury
- Naso-frontal tract injuries with obstruction best managed by obliteration or cranialization (complication rates: 9, 10%)
- Fat obliteration and osteogenesis highest complication rates (22, 42.9%)

Early Complications

- Less than 6 months after injury
- Meningitis

 - immediate repair of dural defect and cranialization

- Sinusitis

 - decongestants, antibiotics

 -surgical intervention may be necessary

Late Complications

- Chronic headache most common
- Mucocele
- Mucopyocele
- Osteomyelitis
- Anosmia
- Cosmetic deformity

Mucocele

- Arises from mucosa trapped between fracture segments or left behind during obliteration
- drainage obstruction results in accumulation of mucus, distension
- Bone resorption via PGE2, collagenase and other enzymes produced by sinus epithelium
- Average interval from injury to mucocele formation, 7.5 years ?

Mucocele

- Manifestations:
  - frontal headache
  - swelling
  - proptosis
  - reduced ocular mobility
- CT

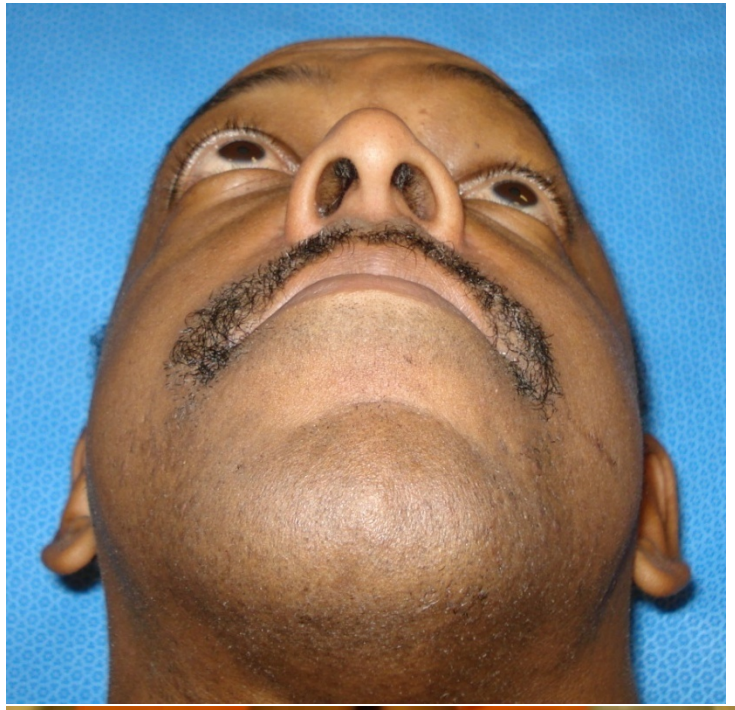

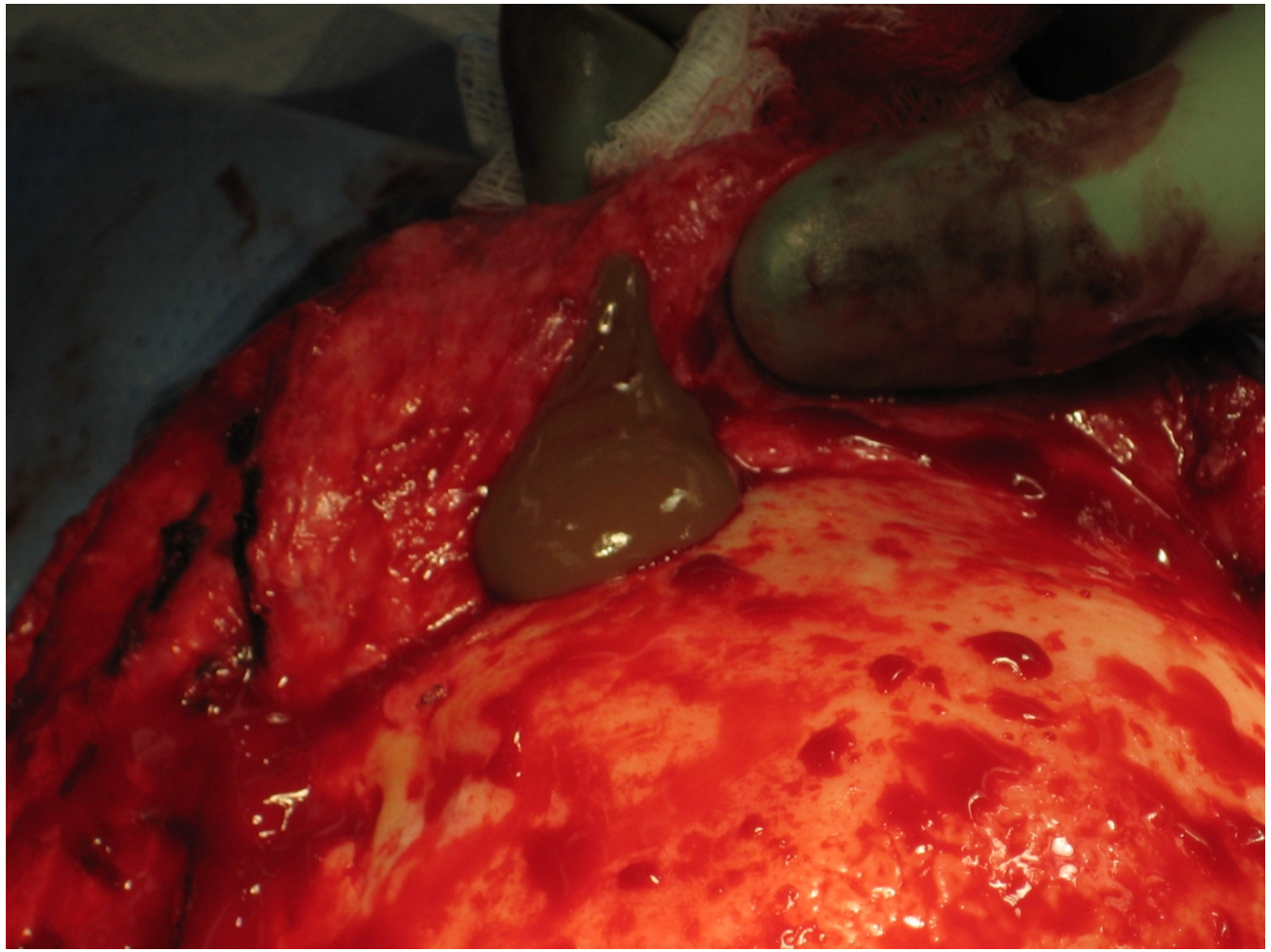

Nasal Fractures

- Most common of all facial fractures
- Injuries may occur to other surrounding bony structures
- 3 types:
  - Depressed
  - Laterally displaced
  - Non-displaced

Nasal Fractures

- Septal injuries are often overlooked because of this diffuse pattern of injury
- Most reductions -closed techniques
- Significant dislocations - open techniques are sometimes necessary
- Secondary revision is deferred until maturation is complete.
- Radiographs – little value

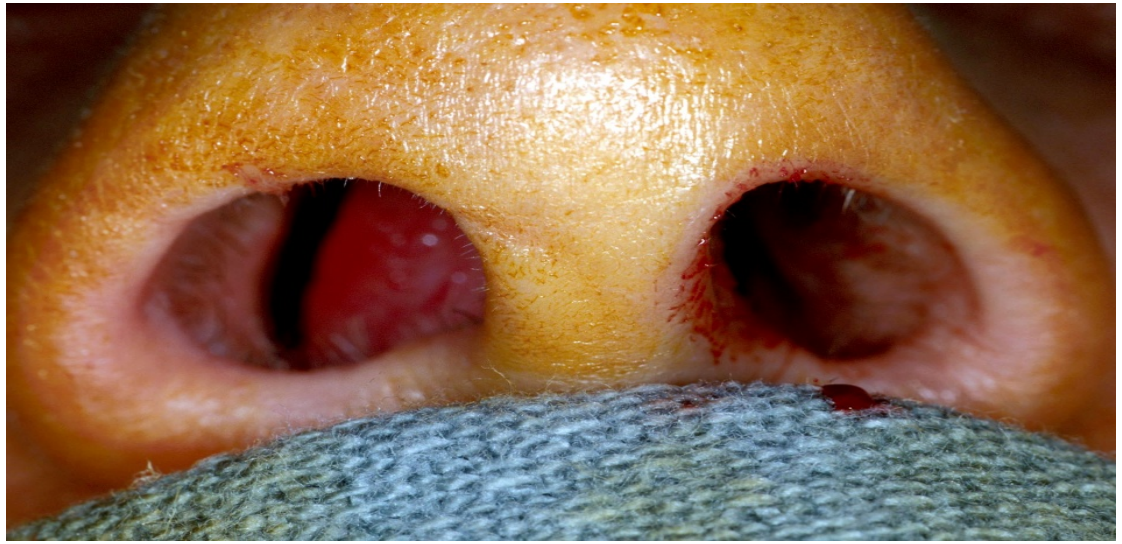

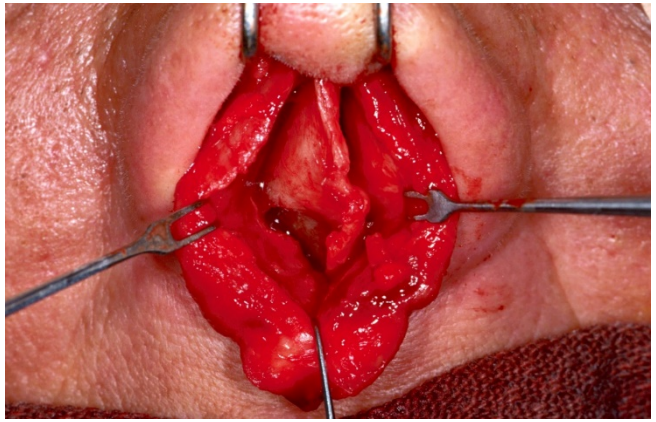

Nasal fractures

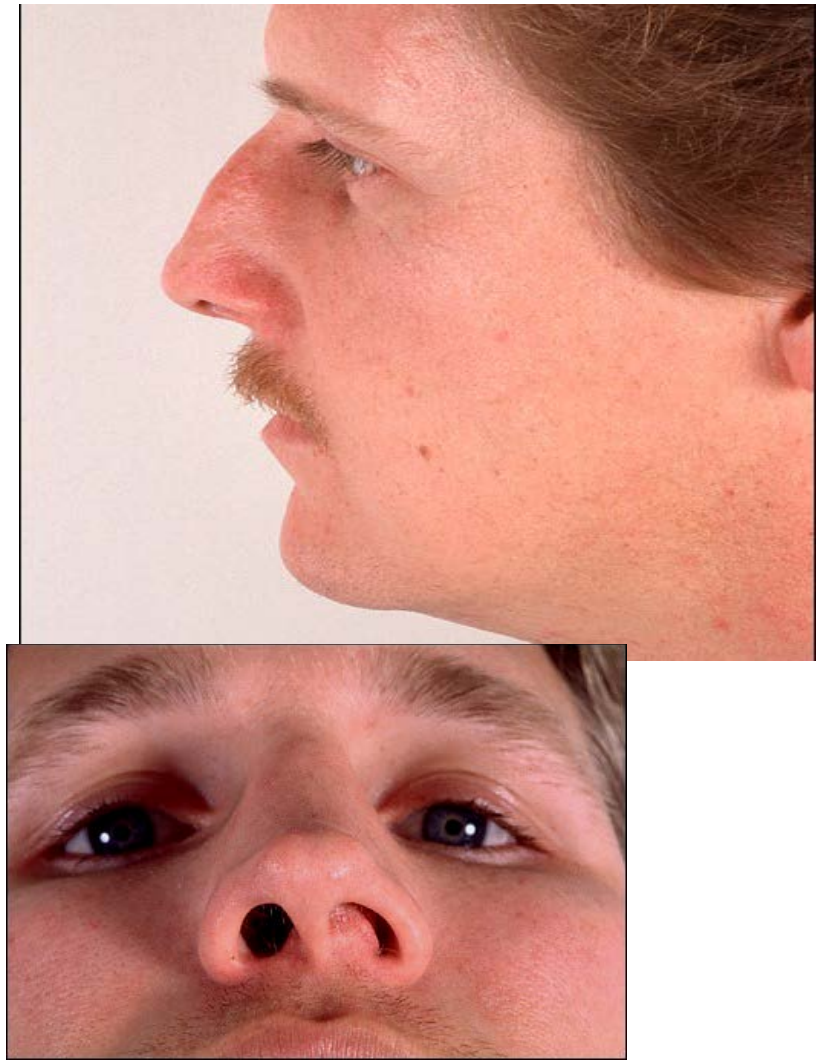

Orbital Blowout Fractures

- Blow out fractures are the most common
- Occur when the globe sustains a direct blunt force
- 2 mechanisms of injury:
  - Blunt trauma to the globe
  - Direct blow to the infraorbital rim

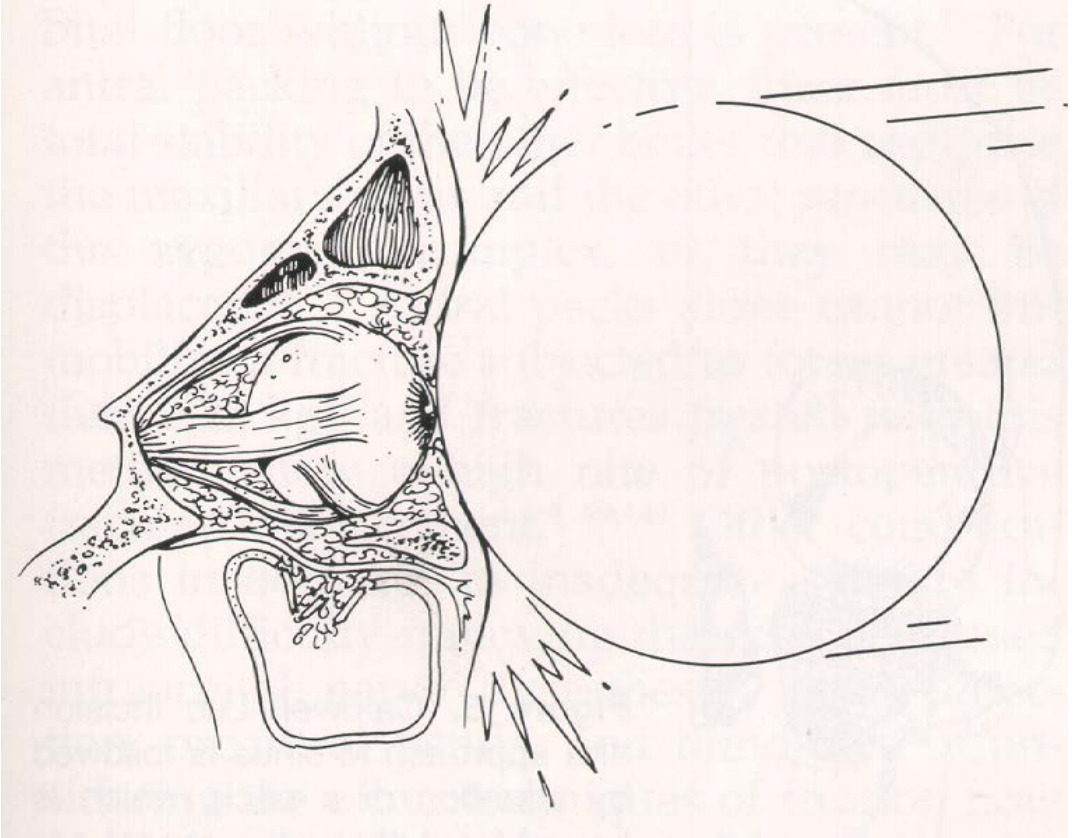

Clinical Features

- Periorbital tenderness, swelling, ecchymosis
- Enophthalmos or sunken eyes
- Impaired ocular mobility
- Diplopia
- Dystopia
- Infraorbital anesthesia
- Step off deformity

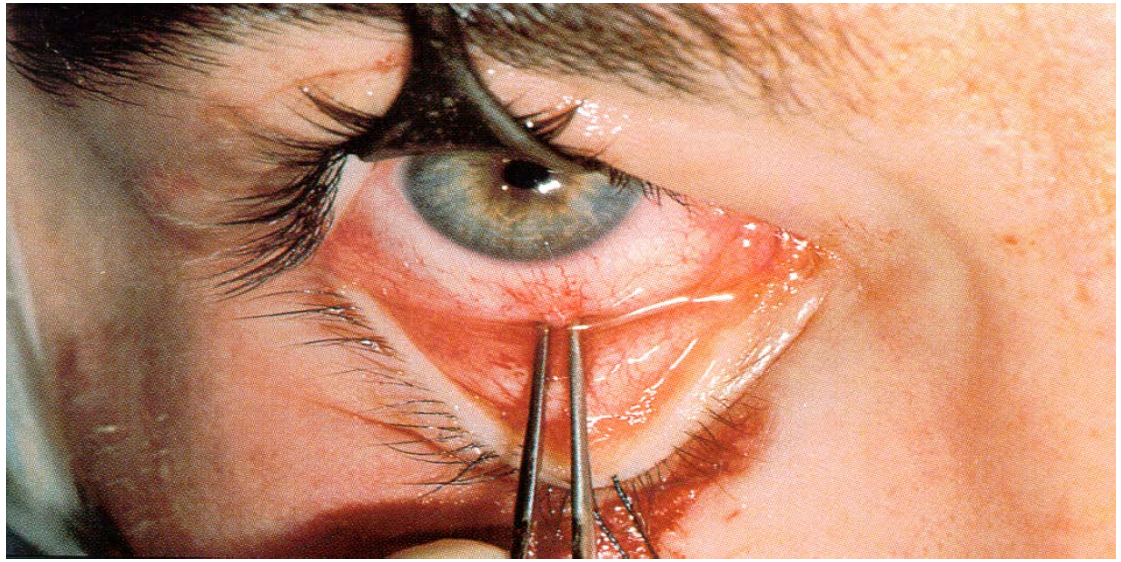

Orbital Trauma



Treatment

- Blow out fractures without eye injury do not require admission
  - Maxillofacial and ophthalmology consultation
  - Tetanus
  - Decongestants
  - Avoid valsalva or nose blowing
- Patients with serious eye injuries – opthamology consult

Orbital Injuries - Enophthalmos

- Displacement of the globe in a A-P dimension
- Clinically significant if >3 mm
- Etiology
  - Expansion of the bony orbital volume
  - Disruption of ligamentous support

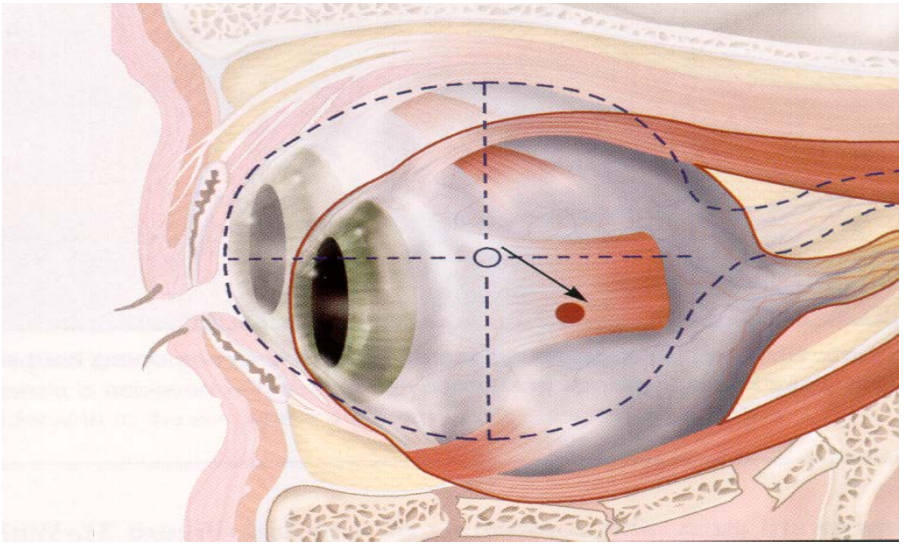

Naso-Orbital-Ethmoidal (NOE) Fracture

- Fractures that extend into the nose through the ethmoid bones
- Associated with lacrimal disruption and dural tears
- Suspect if there is trauma to the nose or medial orbit
- Patients complain of pain on eye movement

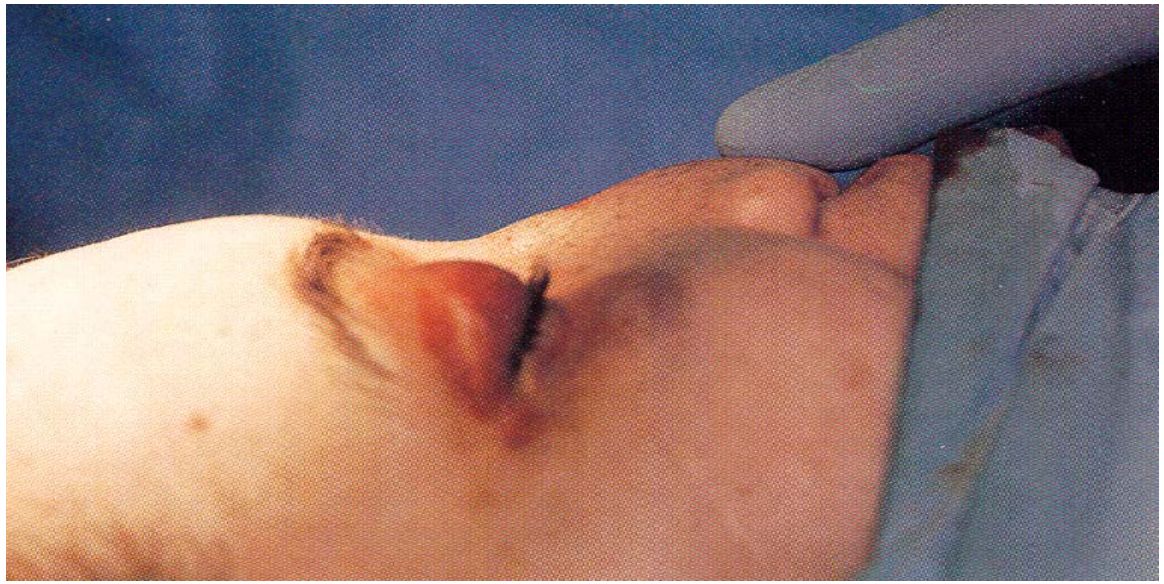

Naso-Ethmoidal-Orbital Fracture

- Clinical findings:
  - Flattened nasal bridge or a saddle-shaped deformity of the nose.
  - Widening of the nasal bridge (telecanthus)
  - CSF rhinorrhea or epistaxis.
  - Tenderness, crepitus, and mobility of the nasal complex.
  - Intranasal palpation reveals movement of the medial canthus.

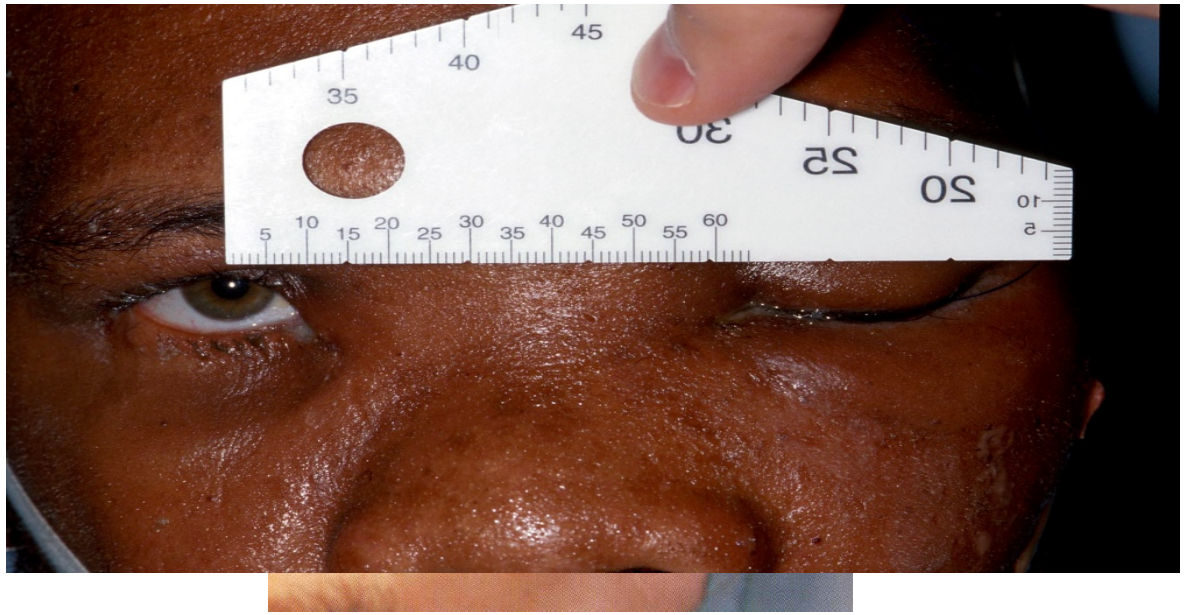

NOE Fractures

- Classification
- Type 1
  - Single central fragment
  - Medial canthus intact
- Type 2
  - Comminuted central fragment
  - Fracture line peripheral medial central canthus
  - Medial canthus attached
- Type 3
  - Comminution with avulsion of canthus

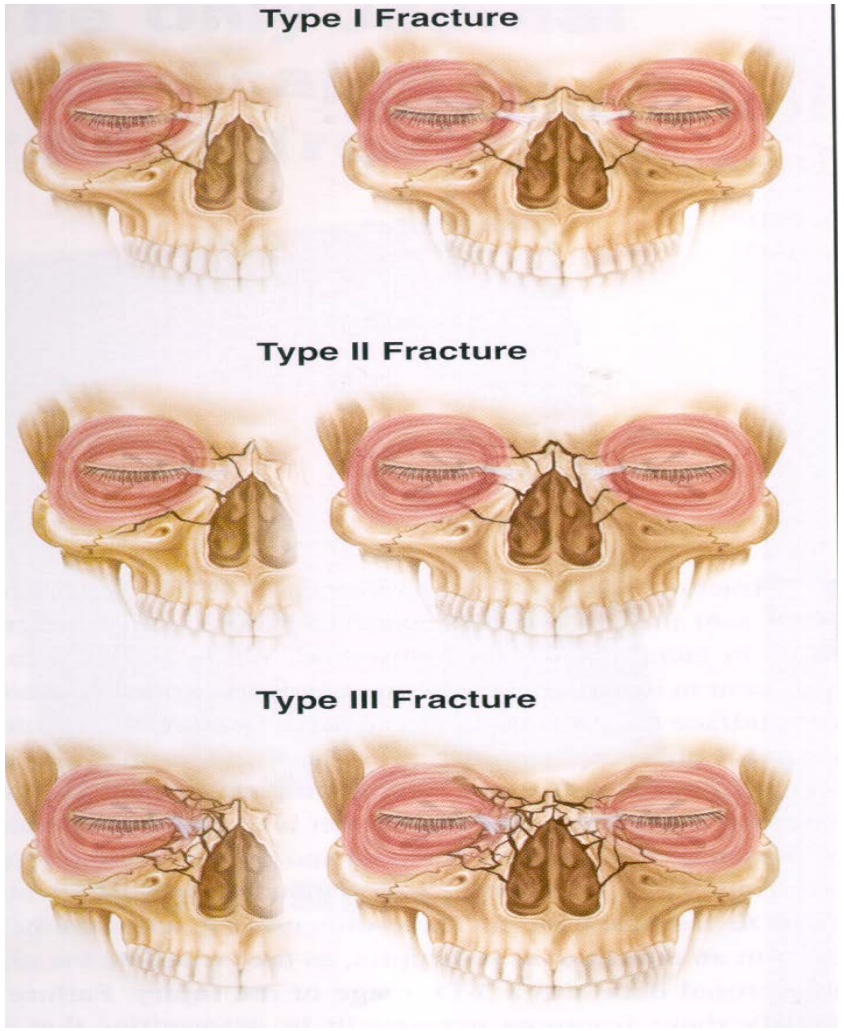

NOE fractures

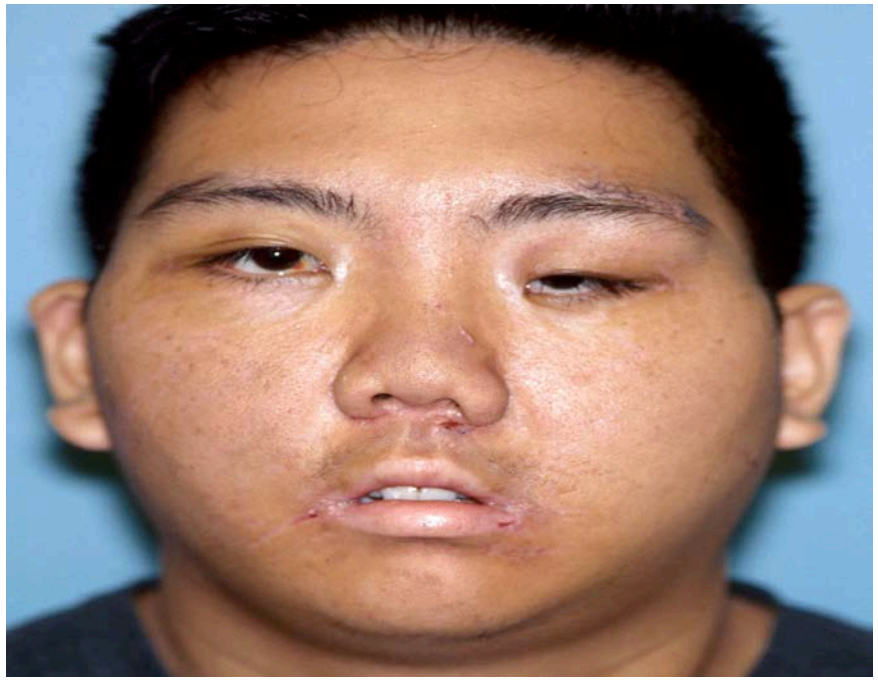

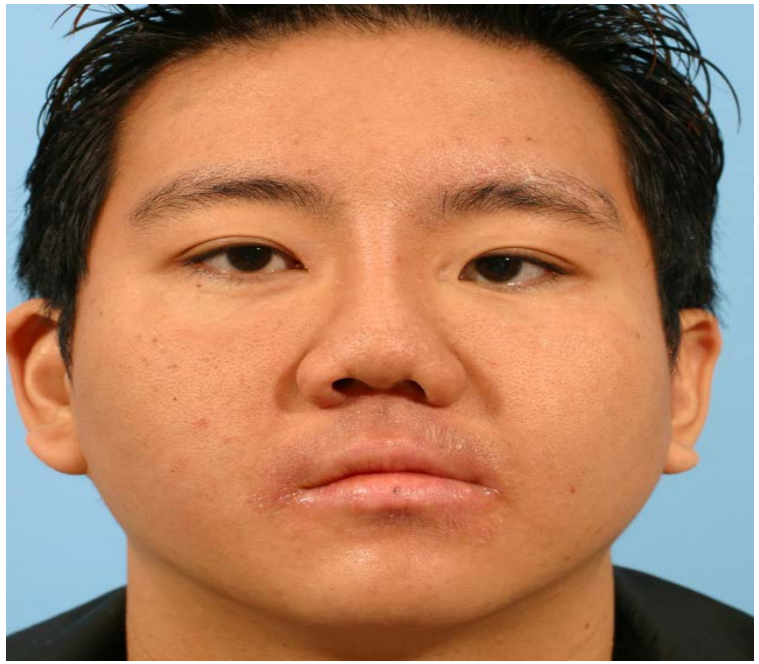

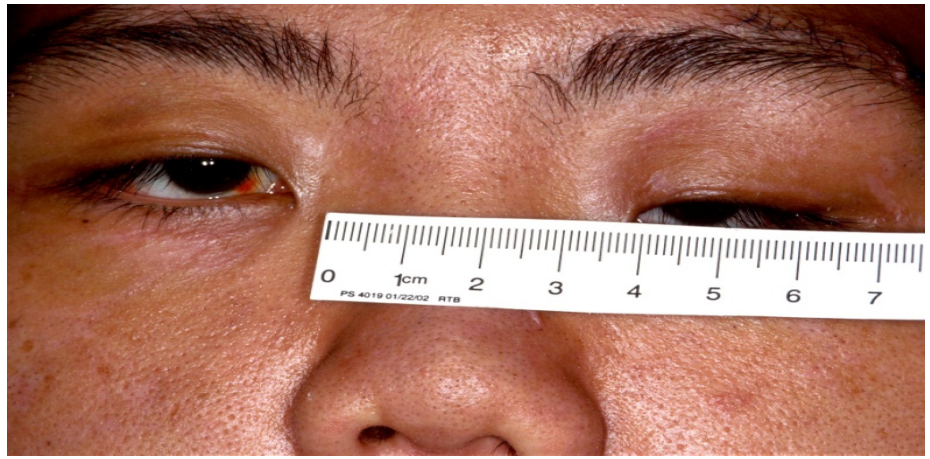

Zygoma fractures

- Zygomatico-maxillary complex fracture (ZMC)
- Orbito-zygomatic fracture
- ~~Tripod Fractures~~

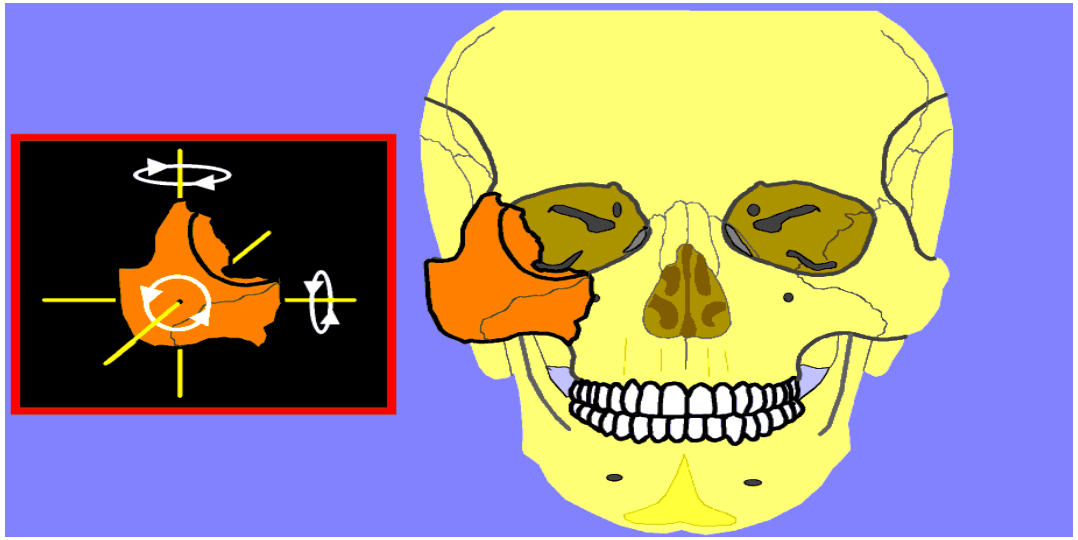

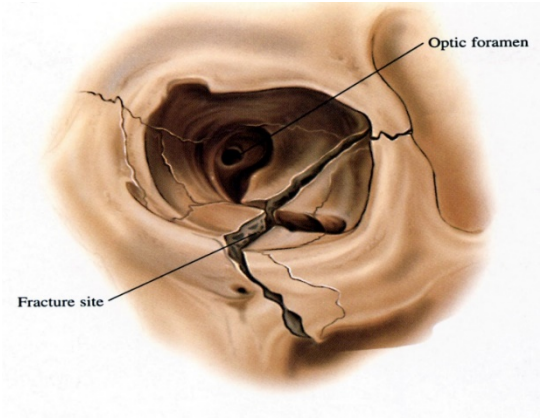

Presentation

- Peri-orbital ecchymosis & swelling
- Flattening of cheek
- Pain
- Trismus
- Orbital rims/ buttress defects
- Ocular signs and symptoms
- Infra-orbital involvement



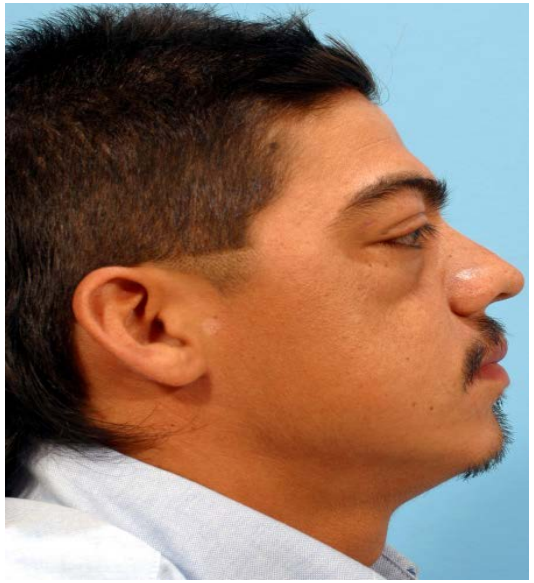

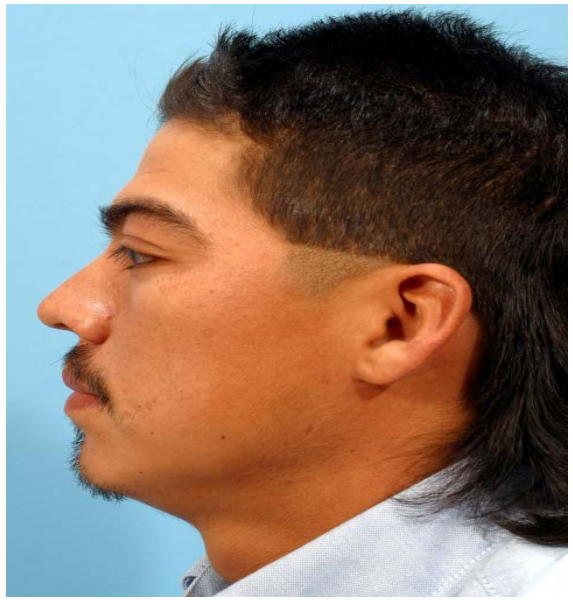

ZMC imaging

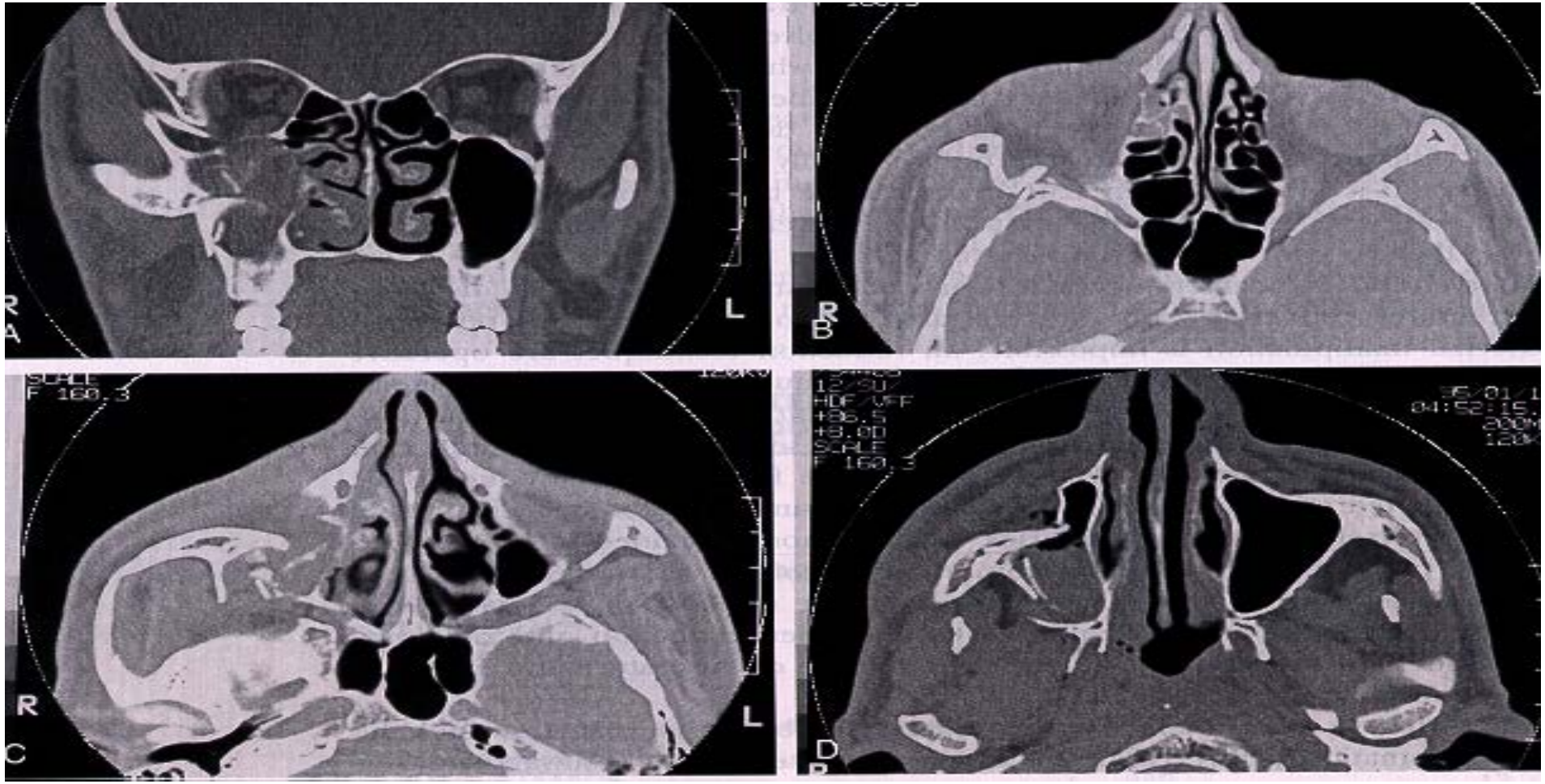

Treatment access

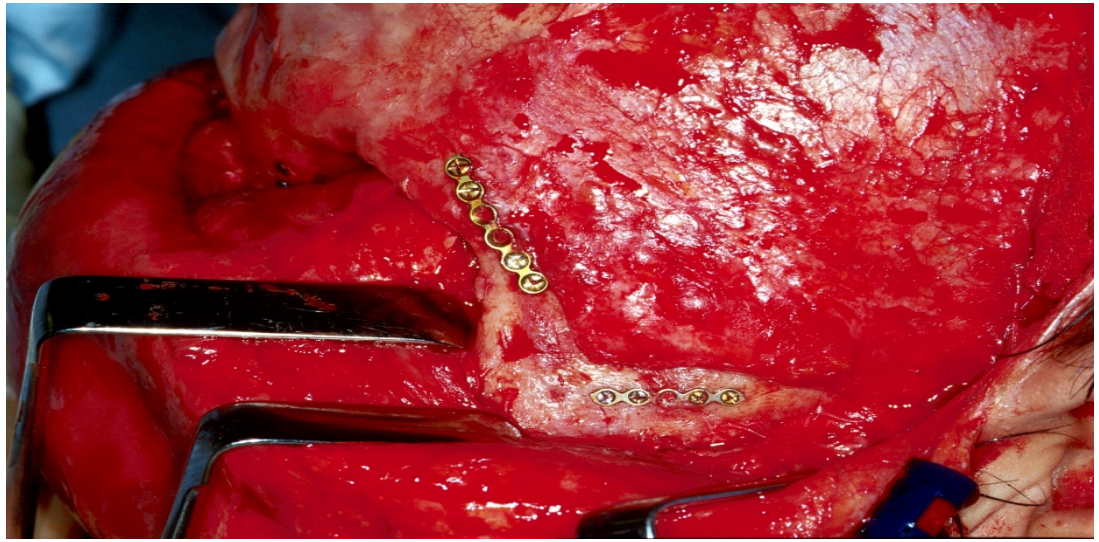

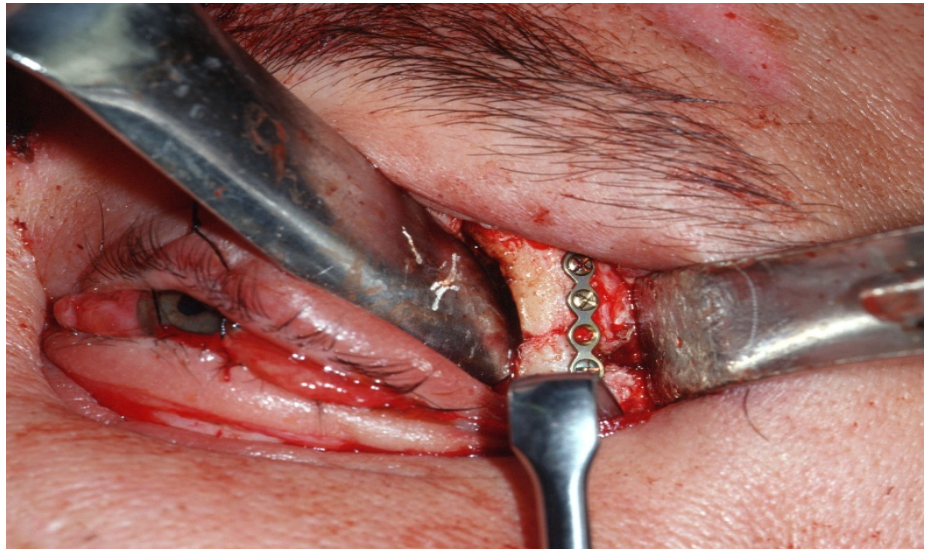

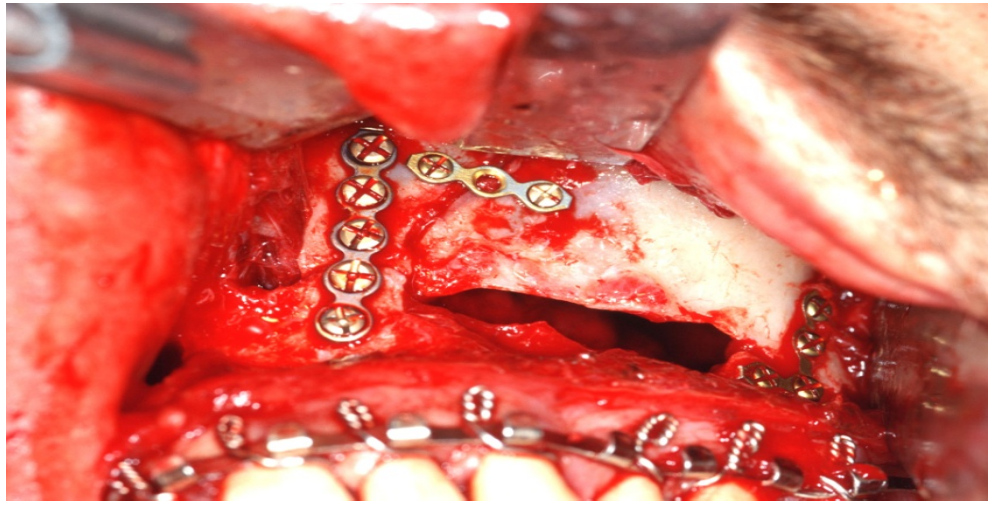

ZMC fractures



Zygomatic Arch Fractures

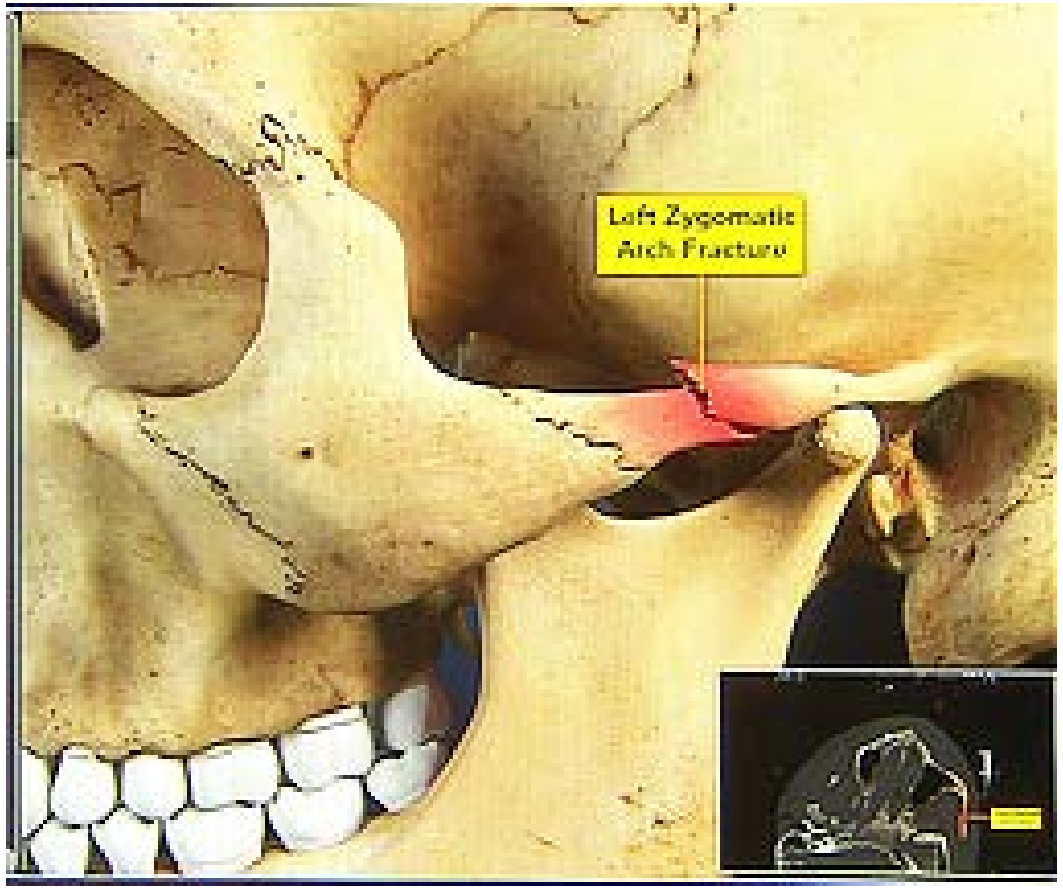

Zygomatic Arch Fractures

Le Fort and Maxillary Fractures

- High energy injuries
- Impact 100 times the force of gravity is required
- Patients often have significant multisystem trauma
- Classified as Le Fort fractures

Le Fort Fractures

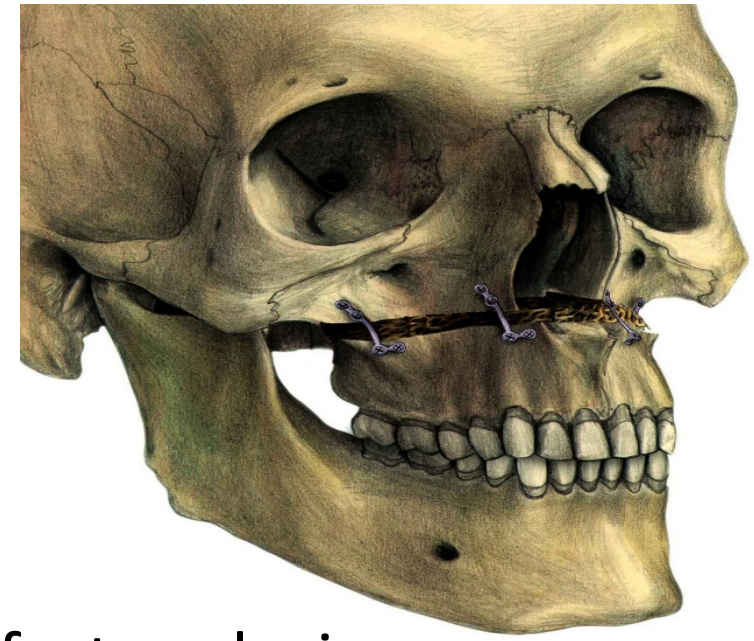

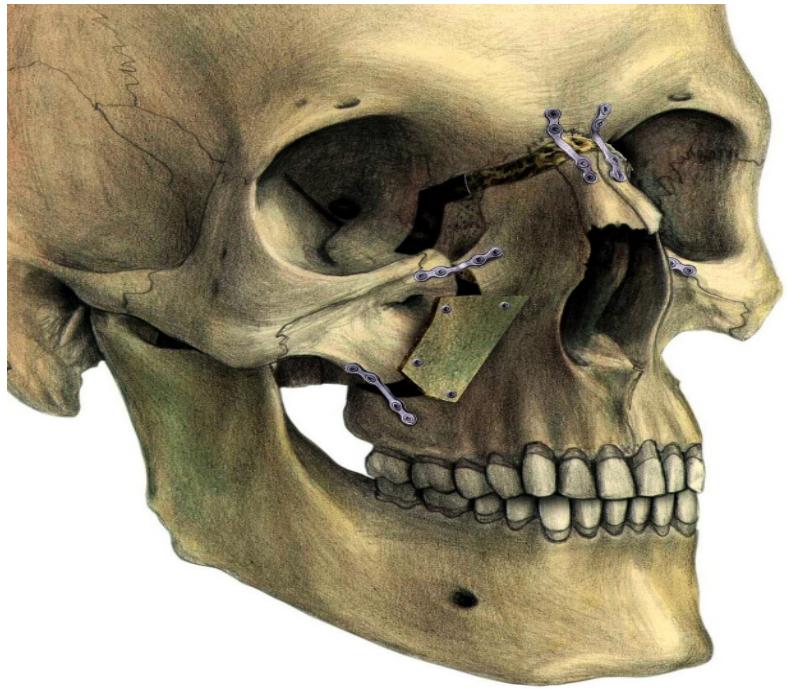

Effect occlusion

- Le Fort I
- Le Fort II
- Le Fort III

Lefort III

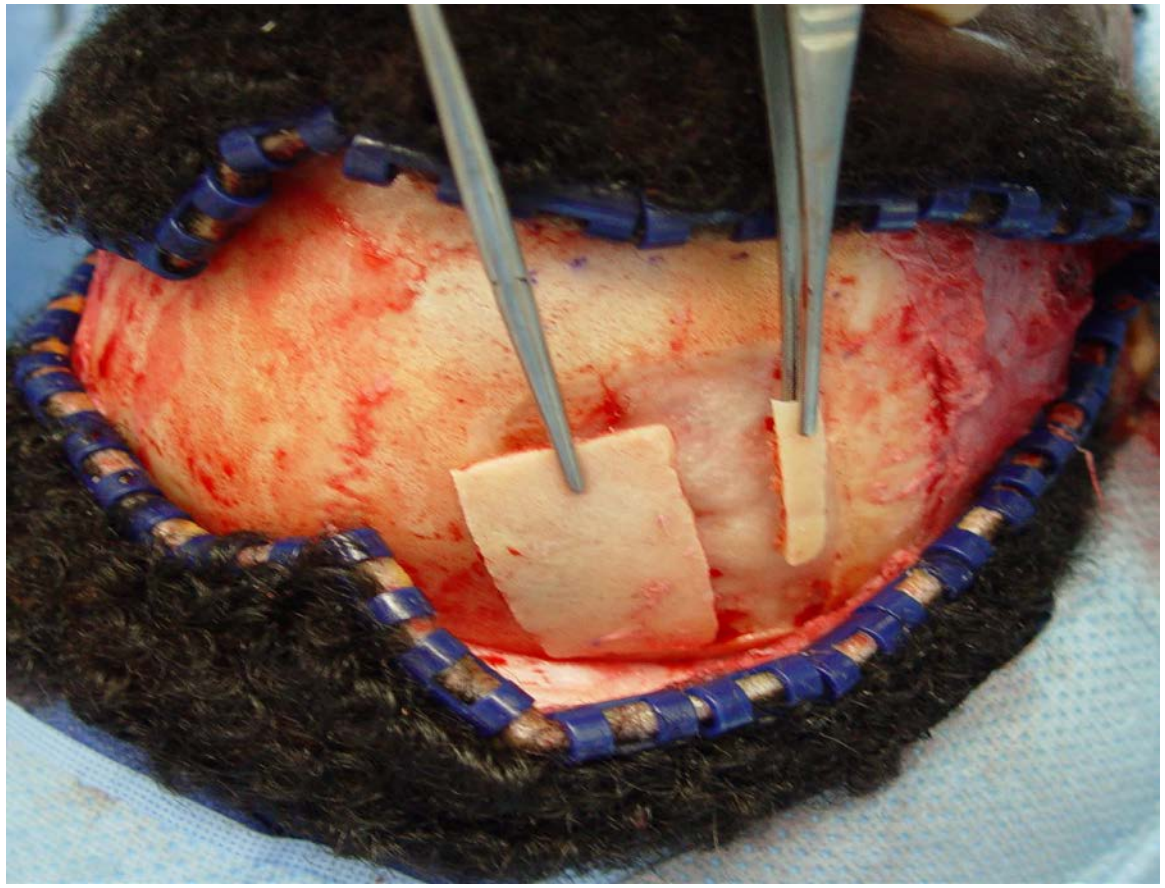

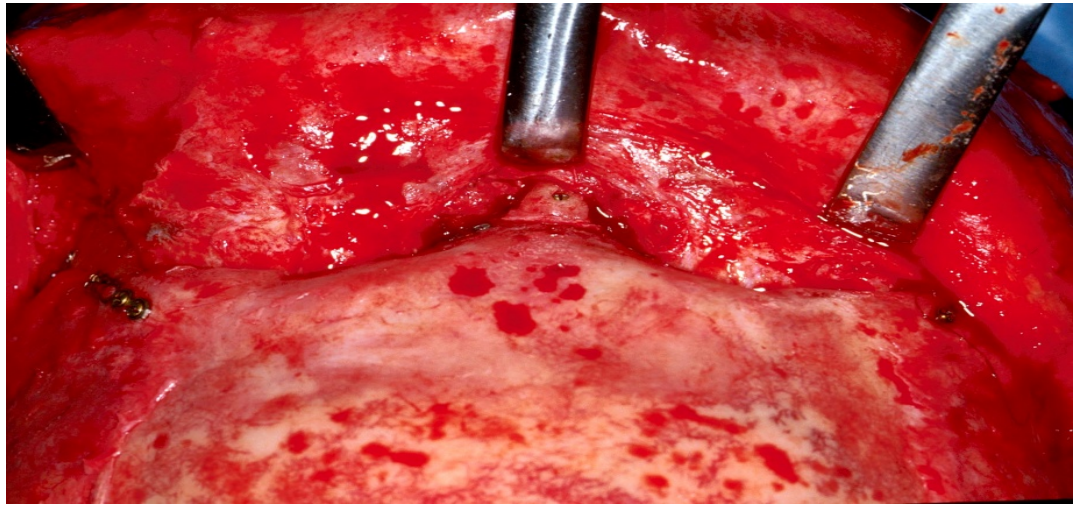

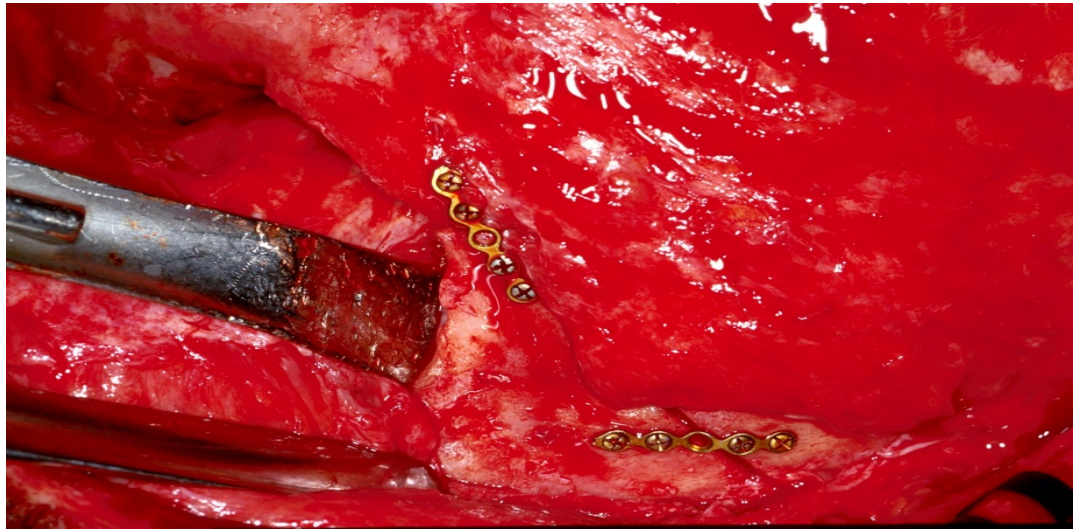

Mandibular Fractures

- Mandible fractures constitute about one-third of the facial trauma
- condyle fractures constitute 60% of the fractures of the mandible

Mandible Fractures

- Symphysis
- Body
- Angle
- Parasymphyseal
- Ramus
- Condylar
- Coronoid
- Alveolar

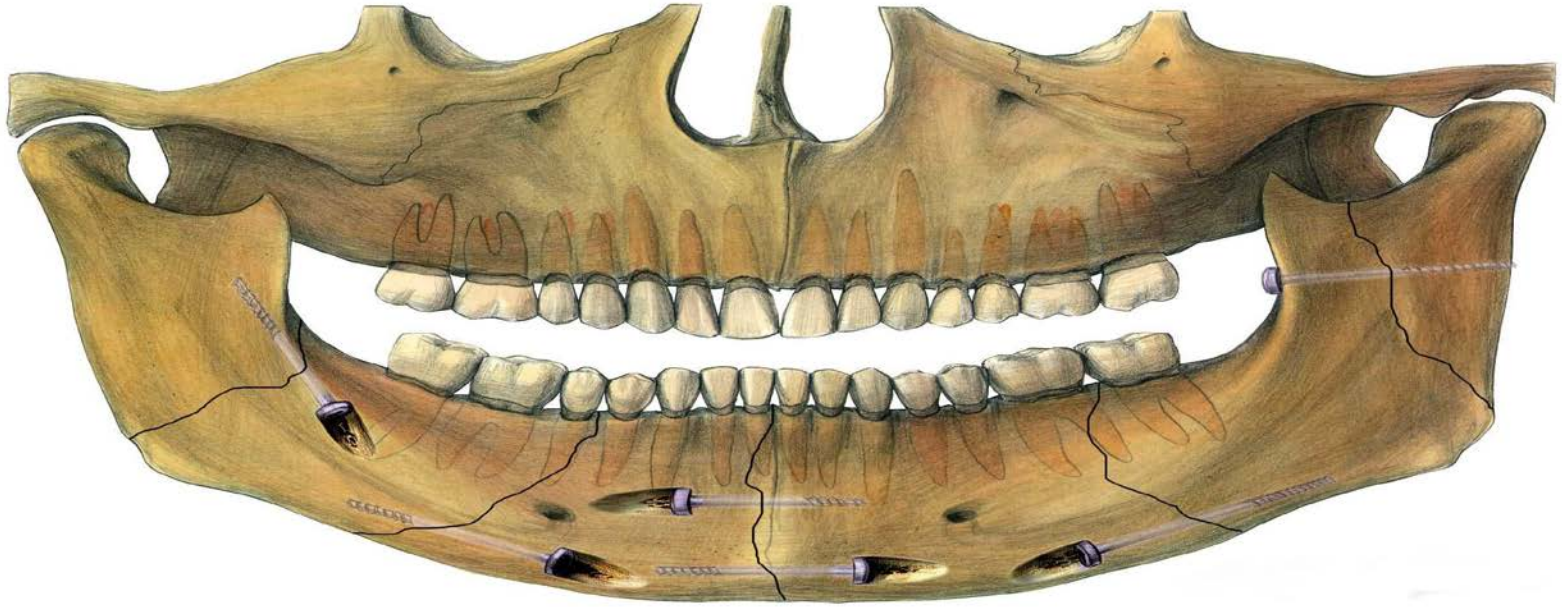

Mandibular Fractures

- Diagnosis
  - Pain
  - Malocclusion
  - Trismus
  - Paresthesia
  - Hemorrhage
  - Ecchymosis and edema
  - blood in the external auditory canal

Fractured Mandible

occlusion, occlusion, occlusion

numb lip, step deformity, *sublingual hematoma*

compound by definition - advise antibiotics

bilateral # more likely, except with isolated condyle #

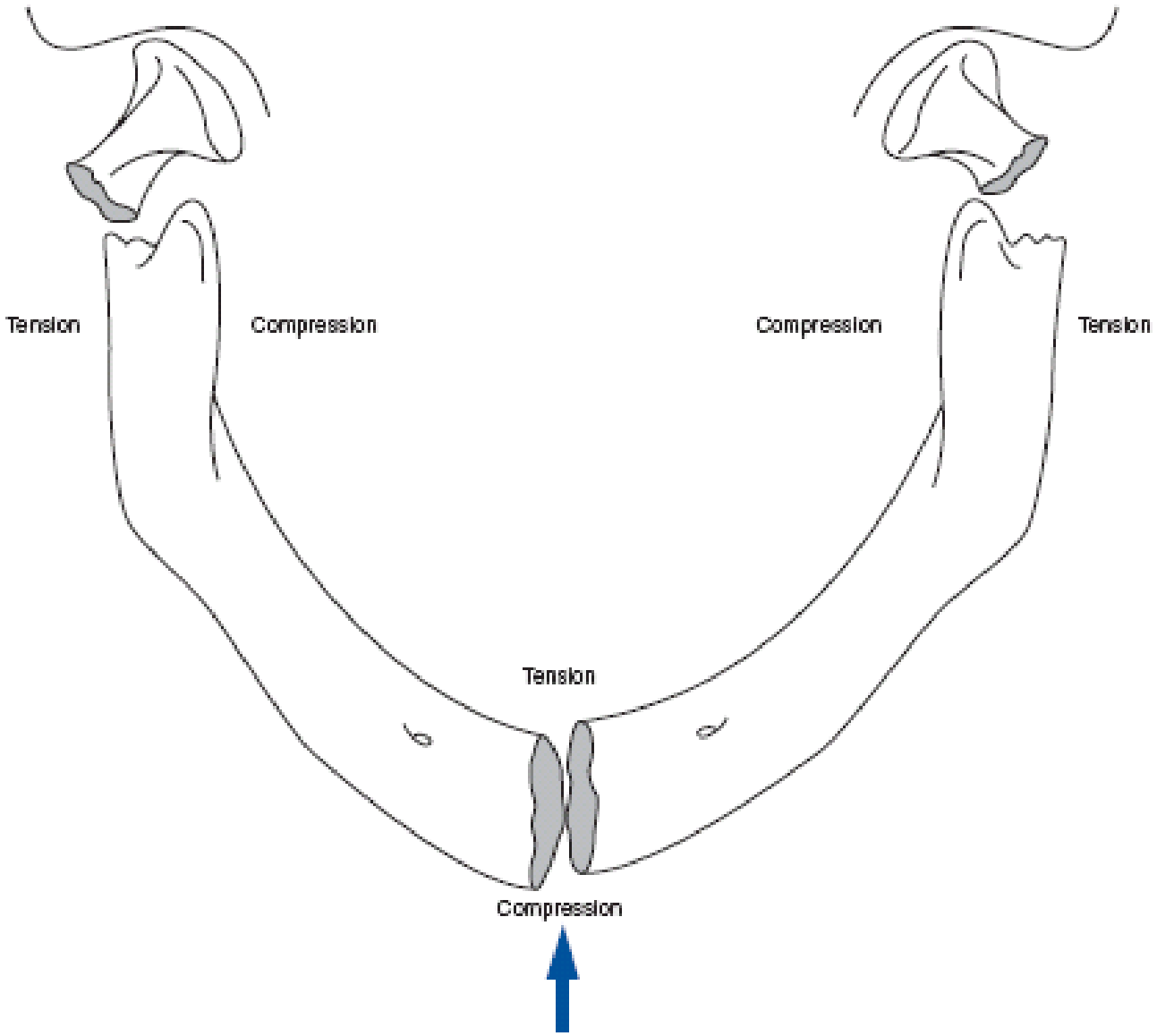
Tension
Compression
Compression
Tension
Tension
Compression

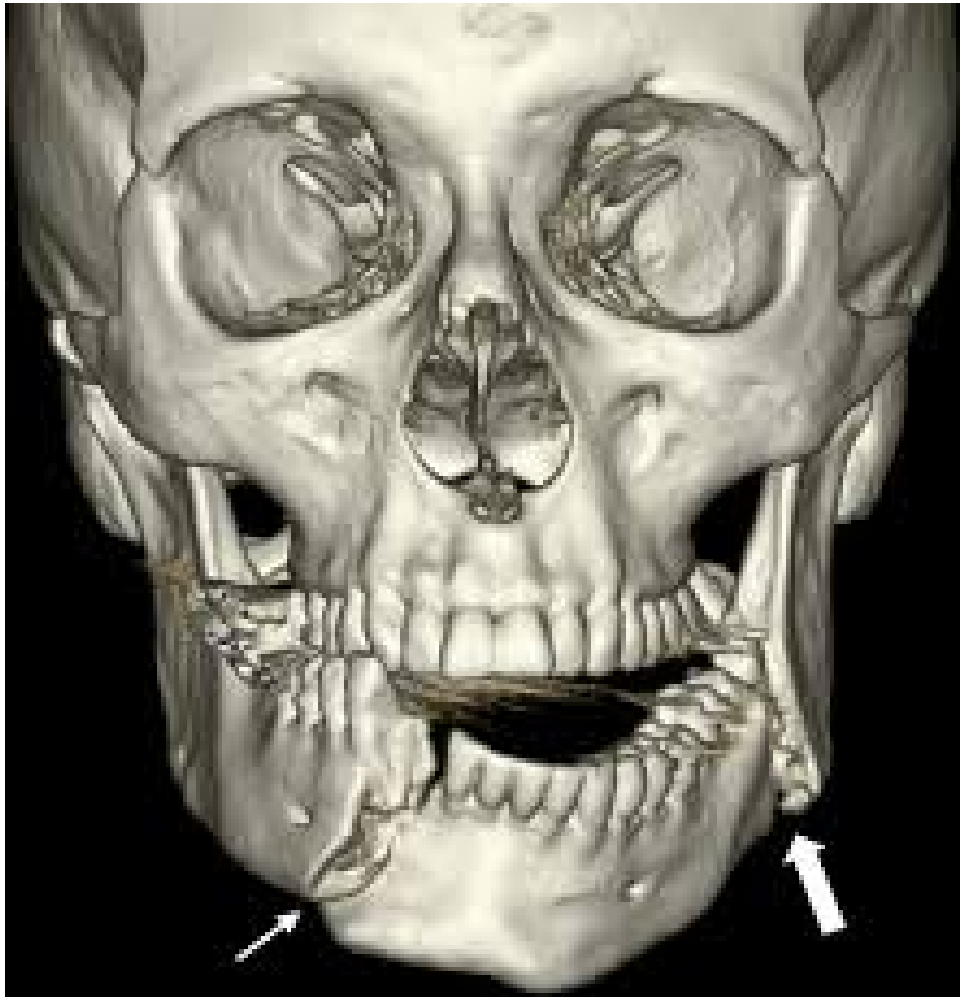

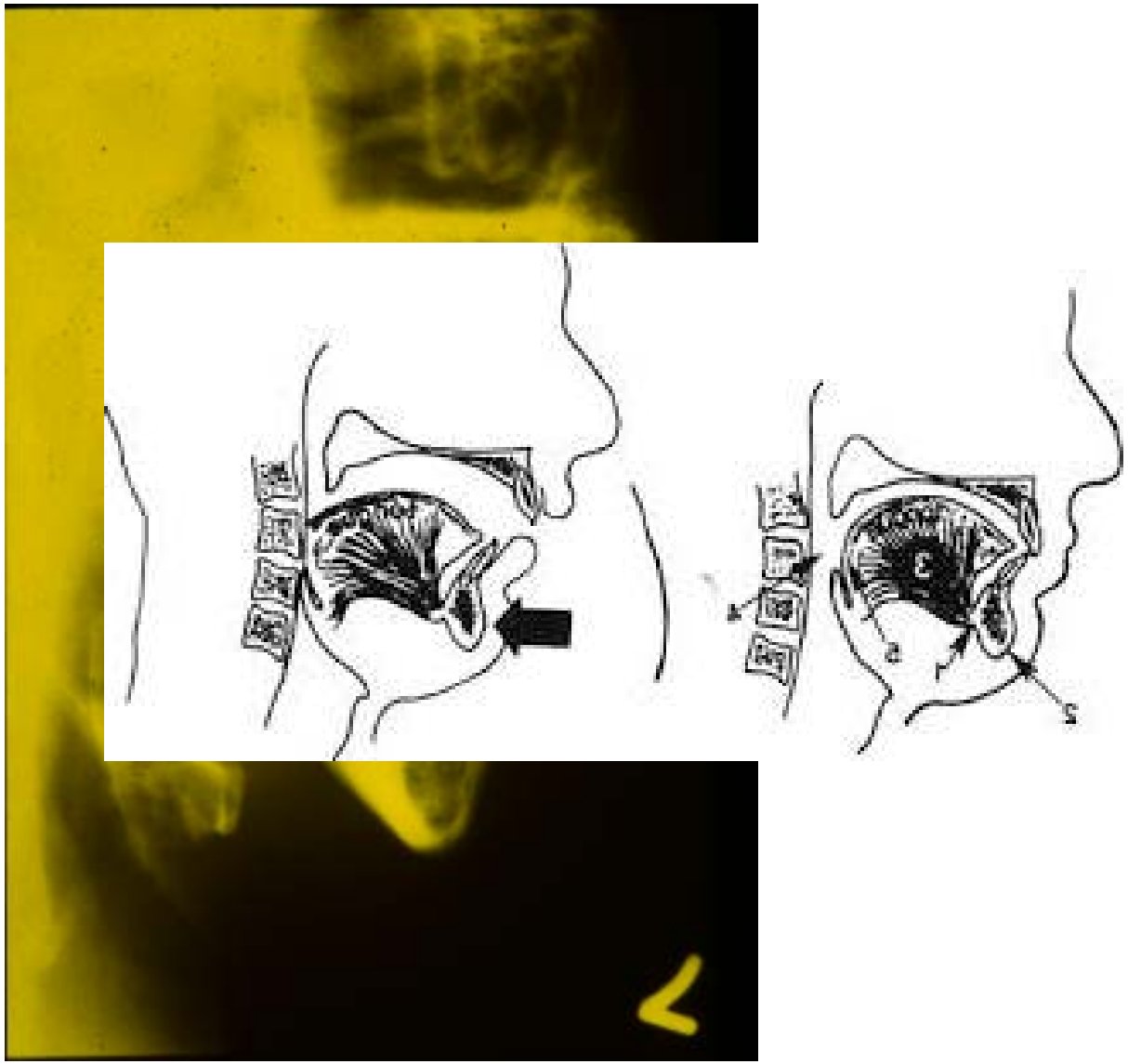

Treatment

- Immobilization of mandible fractures – closed reduction
- ORIF
- Extra-oral vs. intra-oral

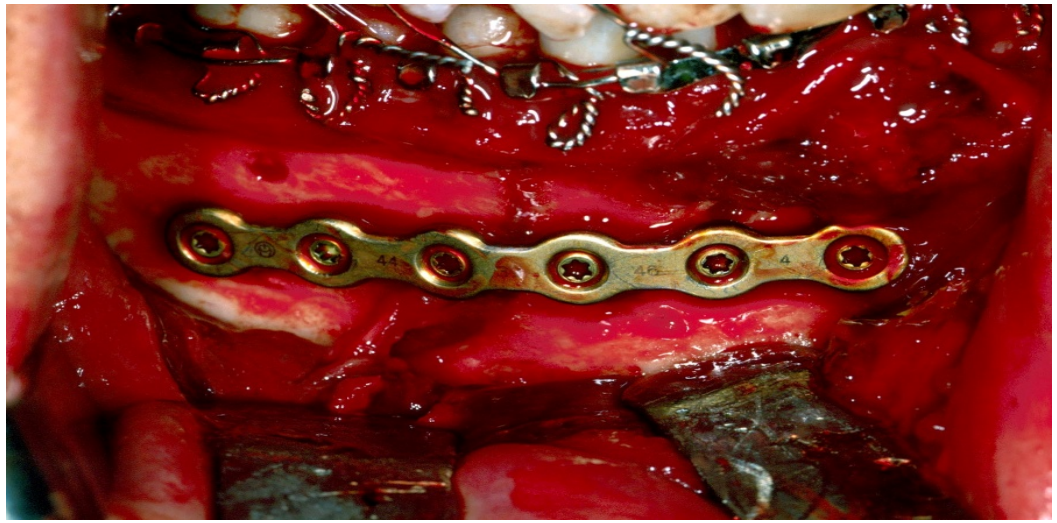

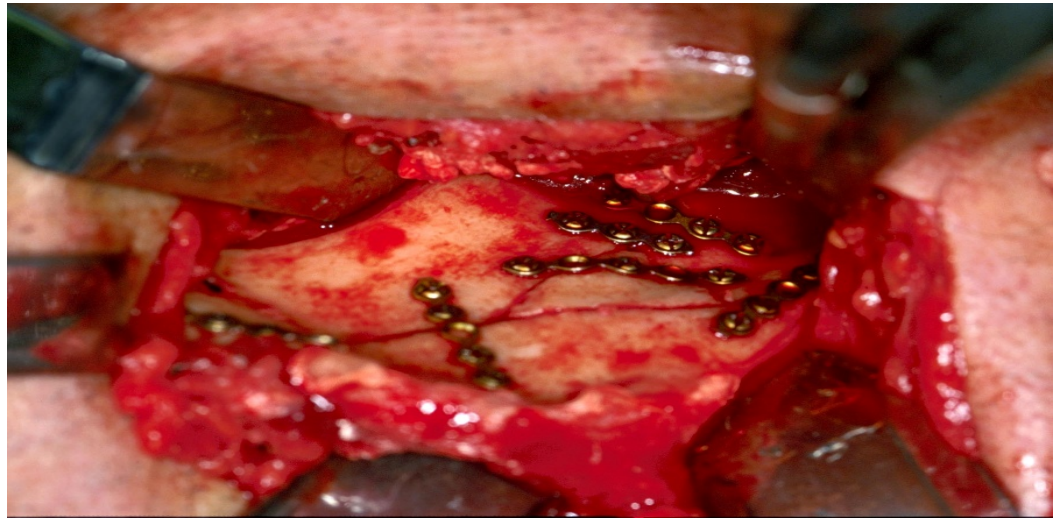

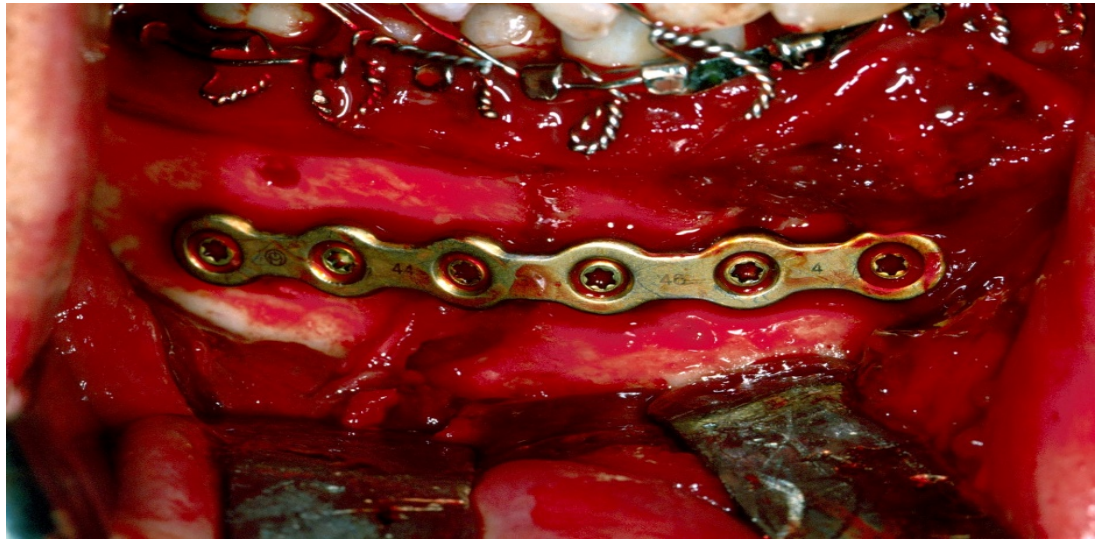

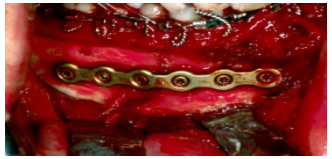

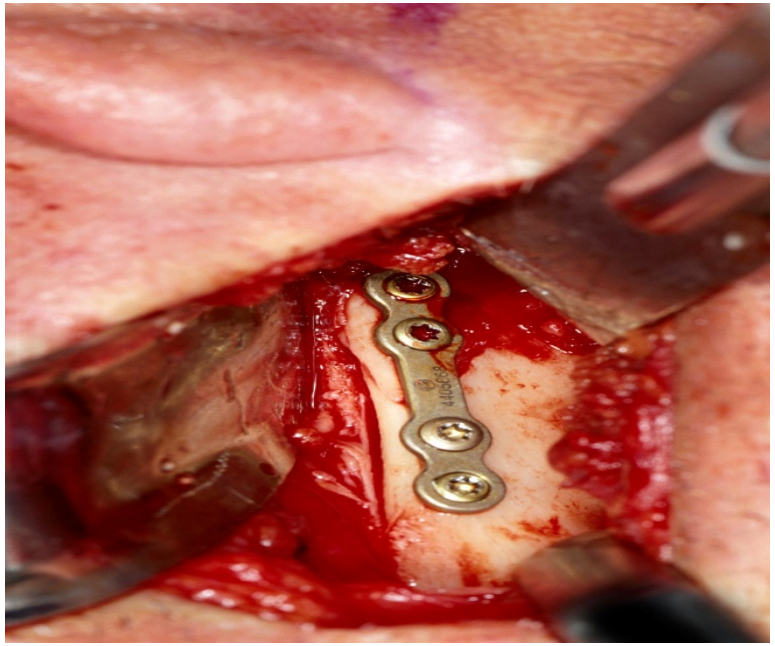

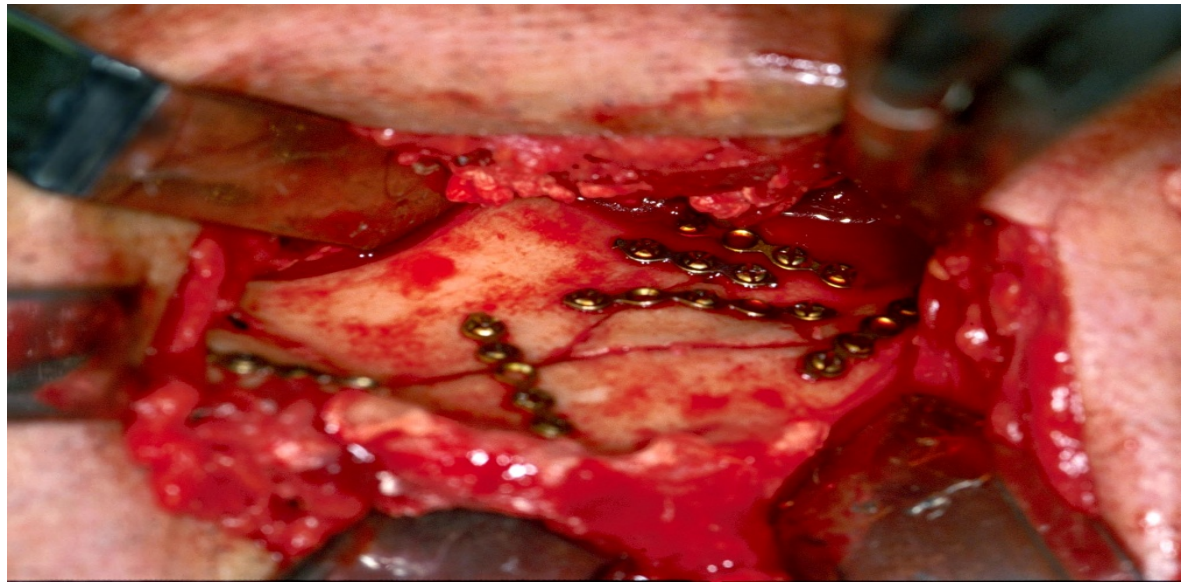


Nikon D600

deepak.krishnan@uc.edu